



ISSN: 2230-9926

Available online at <http://www.journalijdr.com>

# IJDR

International Journal of Development Research

Vol. 12, Issue, 10, pp. 59817-59821, October, 2022

<https://doi.org/10.37118/ijdr.25535.10.2022>



RESEARCH ARTICLE

OPEN ACCESS

## THE CONTRIBUTION OF ELECTROTHERAPY TO REHABILITATION OF CHILDREN WITH OBSTETRIC BRACHIAL PLEXUS PALSY

\*Evgenia Trevlaki

International Hellenic University, Sindos

### ARTICLE INFO

#### Article History:

Received 17<sup>th</sup> September, 2022

Received in revised form

20<sup>th</sup> September, 2022

Accepted 06<sup>th</sup> October, 2022

Published online 30<sup>th</sup> October, 2022

#### Key Words:

Obstetric brachial plexus palsy; Electrotherapy;  
Conservative treatment; Rehabilitation.

#### \*Corresponding author:

Evgenia Trevlaki

### ABSTRACT

**Background:** Obstetric brachial plexus palsy (OBPP) is the palsy of some part or the whole of the upper limb that occurs in the newborn during a difficult delivery. OBPP results from injury to the cervical roots C5–C8 and thoracic root T1 with <1% of births. **Purpose:** The purpose of the review is to investigate the effectiveness of electrotherapy in combination with standard rehabilitation programs in the rehabilitation of OBPP. **Method:** A search in online databases, through search engines as Pub-med, PEDro and Google Scholar, was conducted. Inclusion criteria were studies and reviews published from 2015 to 2021 that used electro-therapy as one of the means of rehabilitation in children and infants diagnosed with any type of OBPP. A total of 9 studies were included in this review. **Results:** In the majority of the studies electrotherapy was used in combination with other therapeutic methods, such as kinesiotherapy, PNF, Bobath, Vojta, splints, massage, warm paraffin wraps, and home exercises, which were applied by the parents. The use of this approach presented a faster and more effective recovery, especially in cases where the muscles of the affected limb are not actively contracting. There are also several cases in which the condition of the affected limb has improved so much that surgery can be avoided. **Conclusion:** The results of this review demonstrates that electrotherapy presents positive effective in the rehabilitation of children with OBPP. Further research is needed in order to clarify the benefits of electrotherapy in infants and children with OBPP.

Copyright © 2022, Evgenia Trevlaki. This is an open access article distributed under the Creative Commons Attribution License, which permits unrestricted use, distribution, and reproduction in any medium, provided the original work is properly cited.

**Citation:** Evgenia Trevlaki. 2022. "The contribution of electrotherapy to rehabilitation of children with obstetric brachial plexus palsy", *International Journal of Development Research*, 12, (10), 59817-59821.

## INTRODUCTION

Obstetric brachial palsy (OBP) is the paralysis of part or all of the upper limb and is a complication that occurs during childbirth (Galbiatti, J.A. *et al.* 2020). The incidence of the condition is 0.5 to 2.6 per 1000 alive births, and the proportion of cases with a permanent functional deficit being about 20 to 30% (Anguelova G.V. *et al.* 2016). OBPP results from injury to the cervical roots C5–C8 and thoracic root T1 (Zafeiriou, D.I., Psychogiou, K. 2008) with <1% of births. OBPP is often self-limiting with reported spontaneous recovery rate of 66 to 82% (2 Lagerkvist A-L *et al.* 2010) (Hoeksma AF *et al.* 2000) (Hoeksma AF *et al.* 2004) (Pondaag W. *et al.* 2004) (Pöyhiä TH *et al.* 2010). Despite neurologic recovery, longstanding and disabling sequelae caused by glenohumeral joint dysplasia (GHD) and contractures of the shoulder are common (Pontus N. Olofsson *et al.* 2019) GHD is a set of skeletal alterations in the glenoid cavity and in the humeral head secondary to OBPP, which reversibility has not been clearly defined (Chagas-NetoFA *et al.* 2016) (Bahm J. 2016). The treatment of choice is reconstructive microsurgery, which is used to establish connections between the nerves of the brachial plexus or through grafts, as well as muscle transfer surgery, through which certain muscles are loosened (Shah *et al.* 2019). One of the most common treatment is conventional physiotherapy with passive mobilizations to prevent shortening,

which is performed within the physiological range of each joint to avoid excessive stretching. Strength exercises and active mobilizations are also applied (Palomo *et al.* 2020). The aim of this review is to examine the effectiveness of electrotherapy in combination with a standard therapeutic program in the functional rehabilitation of the upper limb in children with OBPP.

## METHODS

**Review design:** A search was conducted in electronic databases: PubMed, PEDro and Google Scholar with key words obstetric brachial palsy, electrotherapy, conservative treatment, rehabilitation in Greek and English. The results are presented as per the Preferred Reporting Items for Systematic Reviews and Meta-Analysis (PRISMA) reporting guideline (supporting checklist/diagram) (Moher *et al.* 2009).

**Inclusion criteria:** The inclusion criteria were all type of studies published in English that examined the effectiveness of electrotherapy in the rehabilitation of OBPP. Research published before 2015 was rejected.

**Search strategy:** Initially 93 articles were found of which 3 were duplicates. Of the remaining 90, 43 were rejected due to a non-

relevant title to the review topic. Of the remaining 47 articles, 27 were rejected since the abstract was not relevant to the topic and of the remaining 20, a total of 9 articles met the criteria for inclusion in the review. The search methodology is presented in Figure 1, while the characteristics of the included studies in the Table 1.

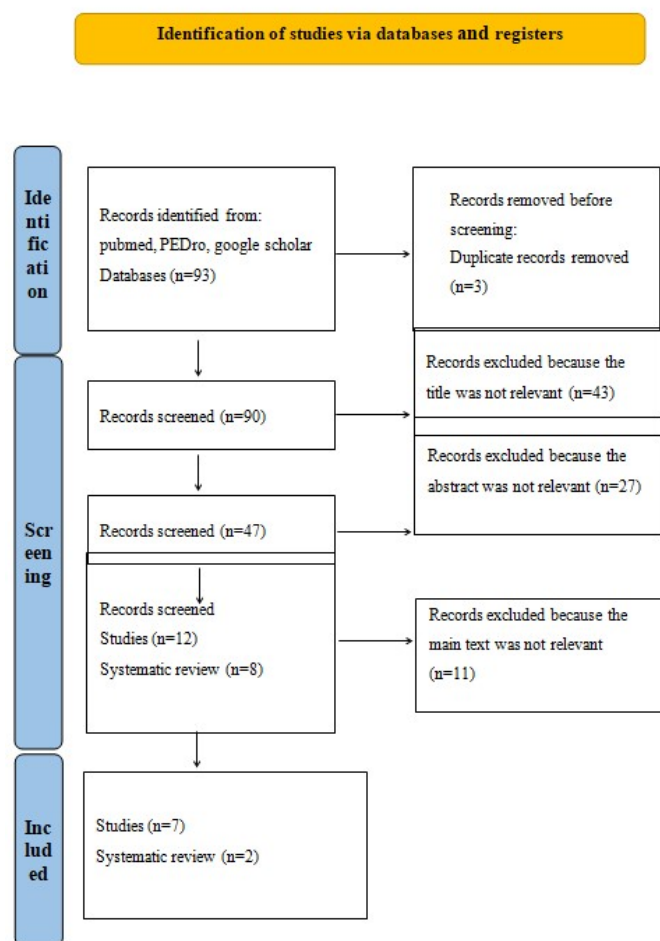


Figure 1. Flow diagram

## RESULTS

The study by Gonçalves R. et al. (2021) evaluated the effect of exercises combined with Functional Electric Stimulation (FES) on the active movement of the upper limb in infants with OBPP with type of damage shearing. The study involved two infants, a 7-month-old girl and a 10-month-old boy, who were assessed weekly on the Active Movement Scale. The current used was symmetrical, with a frequency of 30Hz and a pulse duration of 300ms, the intensity was individually adjusted according to the tolerance of each infant and varied between 15 and 30mA. Whenever the current passed, the infant was encouraged to reach for an object. The treatment lasted for 50 minutes 3 times a week for 6 weeks, of which 20 minutes consisted of FES treatment and active movement stimulation, and the remaining 30 minutes consisted of active movement stimulation exercises without FES. Infants were reassessed twice after a 15- and 30-day intervention-free period. Electrostimulation was acceptable, with no side effects expression of discomfort or pain. The six weeks of intervention resulted in permanent changes in the infants' upper limb function, primarily in increasing active range of motion in shoulder flexion and abduction and elbow flexion. The results of this study suggest the use of electrical stimulation as an adjunct to training the use of the affected upper extremity of infants with OBPP. In a study by Bushra F. et al. (2021) report a 15-year-old teen with chronic OBPP resulting from prolonged natural labor of 18 hours and use of forceps as an assistive device, without any surgery procedure. During treatment, the muscles stimulated were as follows: channel 1 to abductors, shoulder flexors and extensors, channel 2 to elbow

extensors and channel 3 to stimulate wrist extensors. Muscles were stimulated with symmetrical biphasic pulsed current with a pulse duration of 250ms and a frequency of 35Hz. The patient during the treatment had to touch a ball, grasp it while receiving the electrical stimulation, and then release it. Total treatment duration was 30 minutes per session, for 6 days per week, for 4 weeks. After 4 weeks of FES treatment, the results presented positive effects on the recovery of active range of motion of the injured upper limb in chronic OBPP. The patient showed improvement in shoulder flexion and abduction. Before the treatment his modified Mallet scale score was 2 and after treatment his score improved to 3. The Raimondi scale score for the elbow changed from grade 2 to grade 3 and for the hand from grade 2 to grade 4 improving the extent of the wrist. The study by Elnaggar RK (2016) was a randomized controlled trial in which 42 children with OBPP participated. The children were randomly assigned to either the control group, selected exercise program, or the study group, the same program as the control group and neuromuscular electrical stimulation during weight-bearing exercise. The physical therapy program emphasized on loading of the affected arm and functional performance.

The program included the following: (1) weight-bearing exercises for 15 min: body weight transfer to fully extended and externally rotated upper extremity from a seated position, weight transfer to an extended arm from a quadrupedal position, and push-up from a prone position, (2) proprioceptive neuromuscular facilitation (flexion, adduction, external rotation and flexion, abduction, external rotation patterns were used), (3) graded active resistance strengthening exercises, (4) encouraging hand function in reaching for objects, (5) stretching for 20 seconds and then relax for 20 seconds with 3 repetitions in each session, (6) mobilization of the scapula. The total treatment time was 40 minutes, every two days, for 3 consecutive months. In the control group, the same exercise program was applied and additional neuromuscular electrical stimulation only during weight-bearing exercises on the affected limb. The results showed significant differences in both groups when pre- and post-treatment scores were compared. However, when compared the study group showed more significant improvement. A total of 29 patients with Erb-Duchenne, aged 1–7 years, who had not previously received any rehabilitation program and had not undergone surgery were included in Yilmaz V. et al. (2018) study. The physical therapy program was structured as follows: (1) local application of a warm pad to the affected limb for 10 to 20 minutes; (2) passive range-of-motion exercises, including flexion, extension, abduction, and adduction for the shoulder; flexion, extension, supination and pronation for the elbow, and wrist flexion and extension, 2 times per day with 2 sets and 20 repetitions. (3) galvanic current for 20 minutes with a 5-minute break in between, 5 times per week, and (4) occupational therapy to exercise sensorimotor muscles twice a day for 20 minutes.

This 4-week program was run twice at 2-month intervals. Parents were informed for a home exercise program including the same passive range-of-motion exercises during this interval. Patients were divided into three groups according to their age at which they started the physical therapy program as 1-3 years (group 1), 3-5 years (group 2) and 5-7 years (group 3). Patients' range of motion and muscle strength of the relevant joints were assessed before and after the rehabilitation program according to the modified Mallet scale. The results showed a significant improvement in upper extremity function in all age groups with such a rehabilitation program. Berggren J. and Baker L. (2015) in their case study, describe the treatment and surgical interventions provided in the first 2 years of life of a child with a total OBPP on the right brachial plexus and positive Horner's sign. At 2 weeks, passive range-of-motion exercises were started and at 6 weeks, a home program of neuromuscular electrical stimulation with 100ms pulse duration, 20Hz frequency for 15 minutes, 2 times a day for 8 weeks was started. At 3 months, neurosurgery was performed. Constraint induced movement therapy (CIMT) were started at 10 months and applied 4 times per week to increase the use of the affected arm and focus on the development of specific skills. Neuromuscular electrical stimulation was increased to a pulse duration of 150ms and a frequency of 25Hz for 15 minutes, twice a

day for 7 weeks, at 11 months and continued until 17 months. From 18 to 24 months the child continued the CIMT exercises. According to the results at 7 months (4 months after surgery) there were palpable contractions in the shoulder, elbow and finger flexor muscles. Movement against gravity appeared at 12 months at the elbow, at 13 months at the fingers, at 14 months at the shoulder, and at 20 months at the wrist and thumb. The targeted interventions made at specific time intervals had positive effect on strengthening and increasing the active range of motion of the affected limb. In the systematic review by Justice D. et al. (2018) that examined articles on the use of neuromuscular electrical stimulation in the treatment of OBPP. Of the 27 relevant articles only 4 met the inclusion criteria for the review. All 4 studies used different equipment and parameters for neuromuscular electrical stimulation. There was also considerable variation in complementary modalities, including CIMT in one case and Ayurvedic treatment in another. The presence of any kind of concomitant therapy entangles the evaluation of the individual effect of neuromuscular electrical stimulation. The authors report that although the interventions in each article were different, an improvement of the affected limb was observed after neuromuscular electrical stimulation treatment, however, more studies are needed to draw a more definite conclusion.

according to the modified MRC scale. The treatment protocol consisted of passive and actively assisted range-of-motion exercises for the affected limb, neurodevelopmental therapy (Bobath), warm paraffin pads for 20 minutes a day, and electrotherapy, starting at 3 weeks of life. Electrotherapy consisted of 20 minutes of galvanic current (the anode was placed on the arm of the paretic limb and the cathode on the shoulder area) once daily and neuromuscular electrical stimulation to the paretic muscles, also once daily until the muscles reached fatigue. Twenty sessions were held in the clinic and parents were trained with a program of manipulation and exercises at home. From the 6th month of life of the infants, occupational therapy for the paretic limb was included in order to encourage the development of daily activities. Infants were reassessed monthly during the first year of life. The study showed that the majority of fully recovered infants (79%) had upper-type paralysis. Convalescence was less successful in infants with other types of paralysis. Infants with total OBPP showed only partial improvement at 12 months. In Kasnakova V. et al. (2018) study 17 children diagnosed with OBPP participated, and were randomly divided into two groups. The participants were evaluated before and after the intervention with electromyography, the Active Movement scale, the modified Mallet scale and the Manual Muscle test.

**Table 1. Studies included in the review**

Authors	Sample	Intervention	Results
GonçalvesR. et al. (2021)	7-month-old girl 10-month-old boy axillary lesion	Functional electrical stimulation (FES) f=3 Hz, t=300ms and I=15-30mA, combined with active movement for 50min/day, 3 times/week, for 6 weeks	Increase active range of motion in shoulder flexion and abduction and elbow flexion.
Bushra F. et al. (2021)	15-years-old teen Chronic OBPP	FES: t=250ms, f=35Hz, combined with active movement for 30min/day, 6 days/week, 4 weeks	improvement in shoulder flexion and abduction. modified Mallet scale: 2□3 Raimondi scale: for elbow: 2□3 for hand: 2□4 improving the extent of the wrist.
Elnaggar RK (2016)	42 children 3-5 years-old OBPP type: Erb-Duchenne Modified Mallet scale score: 2 Randomly divided into 2 groups	Control group: exercise program Study group: same exercise program and neuromuscular electrical stimulation only during weight-bearing exercises on the affected limb f=10Hz, t=300ms for 40min/day, every 2 days, for 3 months	Significant differences in both groups when pre- and post-treatment scores were compared but, also, between the two groups in favor of the study group when post-treatment scores were compared.
Yilmaz V. et al. (2018)	29 children 1-7 years-old OBPP type: Erb-Duchenne 3 groups: 1 <sup>st</sup> : 1-3 years-old 2 <sup>nd</sup> : 3-5 years-old 3 <sup>rd</sup> : 5-7 years-old	1) Warm pad for 10-20min 2)Passive range-of-motion exercises 2 times/day, 20reps/2sets 3) Galvanic current for 20min, 5 times/week 4) Occupational therapy for 20 min, 2 times/day For 4 weeks	Significant improvement in upper extremity function in all age groups.
Berggren J. and Baker L. (2015)	Case study about the treatment and surgical interventions provided in the first 2 years of life of a child. OBPP type: total injury Positive Horner's sign	At 2 weeks-old: passive range-of-motion exercises At 6 weeks-old: neuromuscular electrical stimulation, t=100ms, f=20Hz for 15min/time, 2times/day for 8 weeks At 3 months-old: neurosurgery At 10 months-old: CIMT 4times/week At 11-17 months-old: neuromuscular electrical stimulation t=150ms, f=25Hz for 15min/time, 2times/day for 7 weeks At 18-24 months-old: CIMT	Positive effect on strengthening and increasing the active range of motion on the affected limb.
JusticeD. et al. (2018)	Systematic review including 4 studies.	All 4 studies used different equipment and parameters for neuromuscular electrical stimulation.	Improvement of the affected limb was observed after neuromuscular electrical stimulation treatment
Živković VD. et al. (2018)	34 infants	1)Passive and actively assisted range-of-motion exercises for the affected limb 2)Bobath 3)Warm paraffin pads for 20min/day 4)Electrotherapy: □Galvanic current 20min □Neuromuscular electrical stimulation 1time/day 5)Exercises at home	79% of full recovery infants had Erb-Duchenne palsy.  Infants with total OBPP showed only partial improvement at 12 months.
Kasnakova V et al. (2018)	17 children Randomly divided into 2 groups.	Study group: Electrotherapy: □infrared radiation for 5-20 min □iontophoresis for 10-30 min □electrostimulation f=0,25-0,5 Hz, t=50-100ms □ultraviolet radiation Also, kinesiotherapy, massage, warm paraffin wraps, pressure therapy, PNF and Vojta method.	In 75% of cases the results were very satisfactory regarding the range of motion in the shoulder.
Tsafa K. and Zaféris X. (2021)	Systematic review including 8 studies	The electrical stimulation process usually involves 15-20 contractions for each muscle group for 2-3 reps in each session.	The electrical stimulation helps to maintain the best possible condition in the muscles by providing the minimal stimulation absent in the affected limb.

Another clinical study, by Živković VD. et al. (2018) included 34 infants treated between 2000 and 2017. Diagnosis was made after clinical examination based on the characteristic position of the affected limb, inability to perform active movements, full passive range of motion, reduced muscle tone and the asymmetric Moro reflex on the side of the lesion. Muscle strength was assessed

The study group received a full physical therapy program. Regarding electrical therapy, the following are applied: infrared radiation to the brachial plexus for 5-20 minutes, iontophoresis for 10-30 minutes, electrostimulation with low frequencies of 0.25-0.5Hz and a pulse duration of 50-100ms and ultraviolet radiation. Additionally, the program included kinesiotherapy, massage, warm paraffin wraps,

pressure therapy, diagonal PNF patterns and Vojta method. In 75% of cases the results were statistically important after the above program, especially regarding the range of motion in the shoulder joint. The authors conclude that a combination program is most appropriate, while physical therapy at home by the parents is necessary. Tsafa K. and Zafeiris X. (2021) conducted a research from June 2010 to June 2020 concerning treatments for OBPP. A total of 8 studies met the inclusion criteria and were included in their review. Comparing the results from these researches they concluded that electrotherapy is considered one of the most important physical therapy techniques. The results presented that it is the chosen recovery method in cases where passive motion is not detected. The choice of electrotherapy helps to maintain the best possible condition in the muscles with electrical stimulation by providing the minimal stimulation absent in the affected limb. The electrical stimulation process usually involves 15-20 contractions for each muscle group for 2-3 repetitions in each physical therapy session.

## DISCUSSION

This review aims to analyze the contribution of electrotherapy to the rehabilitation program of children and infants with OBPP. Three of the articles referred to cases of children with Erb- Duchenne palsy. In addition to the basic physical therapy program, the children also receive electrotherapy program. In the study by Elnaggar RK (2016) are compared two groups of children, one receiving a specific exercise program, while the other received additional neuromuscular electrical stimulation during weight-bearing exercises, and observed greater improvement in the group with the additional electrotherapy program. Also, in the studies by Yilmaz V. et al. (2018) and Živković VD. et al. (2018) are analyzed cases of children whose rehabilitation program, apart from the basic physical therapy program, includes 20 minutes of galvanic current. In both studies the children have a significant improvement in the mobility of their affected limb. In the study of Živković VD. et al. (2018) 79% of fully recovered children had Erb- Duchenne palsy, while those with total OBPP showed partial improvement at 12 months of treatment. Therefore, neuromuscular electrical stimulation and galvanic current seem to contribute positively to the rehabilitation of children with Erb-Duchenne palsy. Two articles analyzed the contribution of FES in combination with a typical rehabilitation program. In the study by Gonçalves R. et al. (2021) the infants were diagnosed by axotomy, while in the study by Kasnakova V et al. (2018) the type of OBPP lesion is not mentioned. All infants who participated in the program of the first study had full recovery on their mobility of their affected limb after 6 weeks of treatment, while in the second study the 75% of the infants had satisfactory results. Regarding the electrotherapy in the second case, the infants received infrared irradiation for 5-15 minutes, iontophoresis for 10-30 minutes and ultraviolet radiation. In both case studies, the authors suggest the functional electrical stimulation in most cases helps to restore children, when applied additionally to other treatments.

According to research, rehabilitation should start as early as possible to have optimal results (Barbosa AM, et al., 2021). Nevertheless, the study by Bushra F. et al. (2021), which analyzed a case of a 15-year-old teen who had not received any surgical treatment until then, showed that after 4 weeks of FES treatment combined with active movement exercises, there were statistically important effects on the recovery of active range of motion in chronic OBPP. According to the 2 reviews included the results showed that electrotherapy presents statistically important improvement. However, more studies need to be done to draw a more certain conclusion. The review by Justice D. et al. (2018) reported that although the interventions in each article were different, was observed improvement of the affected limb after treatment with neuromuscular electrical stimulation. In agreement the systematic review by Tsafa K. and Zafeiris X. (2021) concluded that electrotherapy is considered one of the most important physical therapy techniques, and it is the chosen restoration method in cases where active contraction is not detected.

## CONCLUSION

The results of this review demonstrates that electrotherapy presents positive effective in the rehabilitation of children with OBPP. In the majority of the studies electrotherapy is used in combination with other therapeutic methods, such as kinesiotherapy, PNF, Bobath and Vojta method, splints, massage, warm paraffin wraps, and home exercises, which were applied by the parents. The use of this approached presented a faster and more effective recovery, especially in cases where the muscles of the affected limb are not actively contracting. There are also several cases in which the condition of the affected limb has improved so much that surgery can be avoided. Further research is needed in order to clarify the benefits of electrotherapy in infants and children with OBPP.

## REFERENCES

- Abid, A. (2016). Brachial plexus birth palsy: Management during the first year of life. *Orthopedics & Traumatology: Surgery & Research*, 125-132.
- Angelova GV, Malessy MGA, Buitenhuis SM, Zwet EW, Dijk JG. (2016). Impaired Automatic Arm Movements in Obstetric Brachial Plexus Palsy Suggest a Central Disorder. *Journal of Child Neurology*, 1005-1009.
- Bahm J. The surgical strategy to correct the rotational imbalance of the glenohumeral joint after brachial plexus birth injury. *J Brachial Plex Peripher Nerve Inj* 2016;11(01):e10–e17.
- Barbosa AM, Machado EP, Arantes APF, Dutra da Silva RC. (2021). Early intervention in obstetric brachial palsy: a review. *Brazilian Journal of Development*, 83605- 83616.
- Berggren J. και Baker L. (2015). Therapeutic application of electrical stimulation and constraint induced movement therapy in perinatal brachial plexus injury: A case report. *Journal of Hand Therapy*, 1-4.
- Bushra F., Shastri K., Motar P. (2021). Implication of Functional Electrical Stimulation on Upper Limb Recovery in A Rare Case of Adolescent Chronic Obstetric Brachial Plexus Injury: A Case Report. *Annals of the Romanian Society for Cell Biology*, 4729-4734.
- Chagas-Neto F A, Dalto V F, Crema M D, et al. Imaging assessment of glenohumeral dysplasia secondary to brachial plexus birth palsy. *Radiol Bras* 2016;49(03):144–149.
- Elnaggar RK. (2016). Shoulder function and bone mineralization in children with obstetric brachial plexus injury after neuromuscular electrical stimulation during weight-bearing exercises. *Am J Phys Med Rehabil*, 239-247.
- Galbiatti, J.A.; Cardoso, F.L.; Galbiatti, M.G.P. Obstetric Paralysis: Who is to blame? A systematic literature review. *Rev. Bras. Ortop.* 2020, 55, 139–146.
- Gonçalves RV., Araujo RC., Gonçalves Ferreira VK. (2021). Effect of reaching training combined with electrical stimulation in infants with brachial plexus palsy: a single subject design. *Fisioterapia e Pesquisa*, 32-38.
- Hoeksma AF, ter Steeg AM, Nelissen RG, van Ouwkerk WJ, Lankhorst GJ, de Jong BA. Neurological recovery in obstetric brachial plexus injuries: an historical cohort study. *Dev Med Child Neurol* 2004;46(02):76–83.
- Hoeksma AF, Wolf H, Oei SL. Obstetrical brachial plexus injuries: incidence, natural course and shoulder contracture. *Clin Rehabil* 2000;14(05):523–526.
- Justice D., Awori J., Carlson S., Chang K., Yang L. (2018). Use of Neuromuscular Electrical Stimulation in the Treatment of Neonatal Brachial Plexus Palsy: A Literature Review. *The Open Journal of Occupational Therapy*. 6.
- Kasnakova P., Torniyova B., Ivanova S., Atanasov P., Dragusheva S., Petkova V. (2018). Analysis of applied medical rehabilitation in cases of obstetric brachial plexus lesion – Erb-Duchenne palsy. *World journal of pharmacy and pharmaceutical sciences*, 1-10.
- Lagerkvist A-L, Johansson U, Johansson A, Bager B, Uvebrant P. Obstetric brachial plexus palsy: a prospective, population-based

- study of incidence, recovery, and residual impairment at 18 months of age. *Dev Med Child Neurol* 2010; 52(06):529–534.
- Moher d, liberati a, tetzlaff J, altmandG; prisMa Group. preferred reporting items for systematic reviews and meta-analyses: the prisMa statement. *Ann Intern Med* 2009;151:264–9, W64.
- Palomo, R.; Sánchez, R. Physiotherapy applied to the upper extremity in 0 to 10-year-old children with obstetric brachial palsy: A systematic review]. *Rev. Neurol.* 2020, 71, 1–10.
- PondaagW, MalessyMJ, vanDijkJG, Thomeer RT. Natural history of obstetric brachial plexus palsy: a systematic review. *Dev Med Child Neurol* 2004;46(02):138–144.
- Pontus N. Olofsson, Alice Chu, Aleksandra M. McGrath. The Pathogenesis of Glenohumeral Deformity and Contracture Formation in Obstetric Brachial Plexus Palsy—A Review. *J Brachial Plex Peripher Nerve Inj* 2019;14:e24–e34.
- Pöyhä TH, Lamminen AE, Peltonen JI, Kirjavainen MO, Willamo PJ, Nietosvaara Y. Brachial plexus birth injury: US screening for glenohumeral joint instability. *Radiology* 2010; 254(01): 253–260.
- Shah, A.S.; Kalish, L.A.; Bae, D.S.; Peljovich, A.E.; Cornwall, R.; Bauer, A.S.; Waters, P.M. Early Predictors of Microsurgical Reconstruction in Brachial Plexus Birth Palsy. *Iowa Orthop. J.* 2019, 39, 37–43.
- Tsafa K. and Zafeiris C. (2021). Physiotherapy management of obstetric brachial plexus palsy: A systematic review of the literature. *Journal of Research and Practice on the Musculoskeletal System*, 71-78.
- Yilmaz V, Umay E, Tezel N, Gundogdu I. Timing of rehabilitation in children with obstetric upper trunk brachial plexus palsy. *Childs Nerv Syst.* 2018;34(6):1153-1160
- Zafeiriou, D.I.; Psychogiou, K. Obstetrical brachial plexus palsy. *Pediatr. Neurol.* 2008, 38, 235–242.
- Živković VD., StankovićI., Dimitrijević L., Čolović H., Spalević M., Savić N. (2018). The role of early habilitation in infants with congenital brachial palsy. *Acta facultatis medicae naissensis*, 289-298.

\*\*\*\*\*