

## MICROSTRUCTURAL ANALYSIS OF KIDNEY STONE EXPELLED DURING THE HOMEOPATHIC TREATMENT - A CASE STUDY

<sup>1</sup>Ashish Kumar Jaiswal, <sup>2</sup>Amiya Nand Dev Goswami and <sup>3</sup>Sukhvir Singh

<sup>1</sup>Sr. Homeopathic Medical Officer In-charge, CGHS, Ministry of health & FW (Govt. of india), New Delhi, India

<sup>2</sup>Dean, Faculty of Medicine, JRN Rajasthan Vidyapeeth (Deemed) University, Udaipur-Rajasthan, India

<sup>3</sup>Emeritus Scientist CSIR- National Physical Laboratory, New Delhi, India

### ARTICLE INFO

#### Article History:

Received 19<sup>th</sup> May, 2017  
Received in revised form  
05<sup>th</sup> June, 2017  
Accepted 20<sup>th</sup> July, 2017  
Published online 30<sup>th</sup> August, 2017

#### Keywords:

Microstructural,  
Elemental Analysis,  
Kidney Stone,  
Homeopathic.

### ABSTRACT

A patient, aged about 35 years working as a senior executive in the Govt. of India reported with the severe pain in left side of abdomen on 9/7/2016. On preliminary examination, the patient was found anxious, pulse rapid, respiration hurried and temperature was little elevated. The pain was on the left side of abdomen and was radiating towards the urethra. He had an episode of vomiting also. Patient gave the history of similar attacks of abdominal pain 4-5 months back. The USG report revealed Left UV Junction Calculus of size 12.6 X 6.3 mm. After the proper medication for around 3 months, a stone was expelled through the urethra during urination. The expelled stone was characterized in order to analyze its microstructural features and the elemental composition of the corresponding areas using SEM and EDS respectively. Surprisingly the presence of S and Si along with elements such as O, Ca, Mg, Au and Pd is also revealed as depicted in the EDS spectra of the corresponding area of the stone sample under investigation

Copyright ©2017, Ashish Kumar Jaiswal et al. This is an open access article distributed under the Creative Commons Attribution License, which permits unrestricted use, distribution, and reproduction in any medium, provided the original work is properly cited.

Citation: Ashish Kumar Jaiswal, Amiya Nand Dev Goswami and Sukhvir Singh. 2017. "Microstructural analysis of kidney stone expelled during the homeopathic treatment – A case study.", *International Journal of Development Research*, 7, (087), 14309-14314.

### INTRODUCTION

Kidney stone disease, also known as urolithiasis, is when a solid piece of material (kidney stone) occurs in the urinary tract. Kidney stones typically form in the kidney and leave the body in the urine stream. A small stone may pass without causing symptoms. If a stone grows to more than 5 millimeters (0.2 in) it can cause blockage of the ureter resulting in severe pain in the lower back or abdomen (Munjaj et al., 2015). A stone may also result in blood in the urine, vomiting, or painful urination. Most stones form due to a combination of genetics and environmental factors. Risk factors include high urine calcium levels, obesity, certain foods, some medications, calcium supplements, hyperparathyroidism, gout and not drinking enough fluids.

Stones form in the kidney when minerals in urine are at high concentration. The diagnosis is usually based on symptoms, urine testing, and medical imaging. Stones are typically classified by their location: nephrolithiasis (in the kidney), ureterolithiasis (in the ureter), cystolithiasis (in the bladder), or by what they are made of (calcium, uric acid, struvite, cystine).

#### Signs and symptoms

Upper pole/ mid renal stones are more likely than the lower pole stones to become symptomatic (Dropkin Benjamin et al., 2015). The hallmark of a stone that obstructs the ureter or renal pelvis is excruciating, intermittent pain that radiates from the flank to the groin or to the inner thigh. Renal colic caused by kidney stones is commonly accompanied by urinary

urgency, restlessness, hematuria, sweating, nausea, and vomiting. Nephrolithiasis is the third commonest disorder of the urinary tract after urinary tract infection and prostatic hyperplasia. About 80% of renal stones are composed of either calcium oxalate or calcium oxalate mixed with calcium phosphate, and 6% to 9% are either uric acid or cystine stones. In all cases there is an organic matrix of mucoprotein that makes up about 2.5% of the stone by weight (Robbins, 2012).

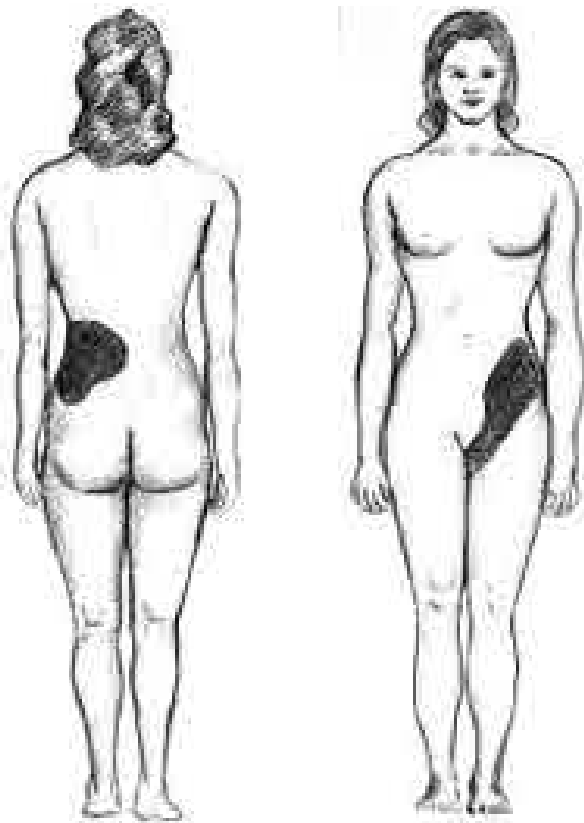


Fig. 1. Sketch diagram showing the typical location of renal colic, below the rib cage to just above the pelvis

### Role of Stone Promoters and Inhibitors

Calcium, oxalates, phosphates, uric acid are stone promoters. Their super-saturation is prevented by inhibitors like citrate, magnesium and pyrophosphate, citrate forms soluble complex with calcium, magnesium and pyrophosphate. Organic inhibitors like nephrocalcin, Tramm-Horsefall proteins, glycosaminoglycans and osteopontin inhibit calcium oxalate crystal growth. Sodium intake should be restricted to 100mEq/d. Increased sodium intake will increase sodium and calcium excretion, increase monosodium urates, increase the relative saturation of calcium phosphate, and decrease urinary citrate excretion. All of these factors encourage stone growth (McPhee Stephen, 2012).

### Case Report

A 35 years old patient, reported with the severe pain in left side of abdomen on 9/7/ 2016. On preliminary examination, he was found anxious, pulse rapid and temperature was little elevated. The pain was changing its character rapidly and many times it felt like stitching in the region of kidney, and was radiating (Chaudhuri, 2006) towards the genitals. Often the burning sensation was also present.

Mild headache with sensation of constriction was present on forehead. Urinary problem was aggravated by motion. He had an episode of vomiting also. Patient felt mentally and physically tired<sup>6</sup> and gave the history of similar attacks of abdominal pain 4-5 months back. There was associated frequent and painful urination with pain and sensation of fullness of the lower abdomen (left side). There was no family history of Urolithiasis. The USG revealed – “Left UV Junction Calculus of size 12.6 X 6.3 mm.” Report of the USG is as shown in Fig.2.

**Totality of Symptoms:** Pain in the left side of abdomen with rapid change in character (Boericke William et al., 2012), stitching, burning pain, sensation of constriction on forehead, urination dribbling by drops, frequent urination, dysuria, painful retention of urine, sensation of fullness of bladder, frequent morbid desire, urging to urinate, urinary problems aggravated by motion.

**Repertorisation and Prescription:** The repertorisation was done using software (RADAR 10). In consultation with the Materia Medica, *Berberis vulgaris 30C* was prescribed. Fig. 3 represents the Repertorisation of the present case.

In the subsequent follow-ups, no earlier symptoms were reported by the patient and no new symptoms found to be appeared. The stone thus expelled has been shown in Fig.5 (size approximately 12mm x 6mm) was investigated for its morphological features and elemental composition analysis using scanning electron microscope(SEM) with an attachment of energy dispersive spectrometer (EDS).

### RESULTS AND DISCUSSION

The case highlights the effectiveness of homeopathic treatment in the expulsion of urolithiasis. On the basis of the totality of the symptoms, the deep acting, antimiasmatic, constitutional, similimum, homeopathic medicine was needed after careful repertorisation and final selection with the help of Materia Medica. The medicine thus selected was *Berberis Vul. 30C* and was prescribed. Sulph., Nux Vom., Ammon., Arsenic., Belladonna, Plumb., Pulsatilla., Merc. Sol and Lycopodium were other high scoring medicines. These drugs can be differentiated on the basis of their characteristics in the Materia Medica. The stone was reported to be expelled and the patient didn't report any urinary complaint thereafter. The USG report as shown in Fig.4 depicts the expulsion of stone.

As evolved stone was characterized in order to investigate the surface morphological details and the elemental compositional analysis of the different areas of the stone. Scanning electron microscope (model EVO MA10 operated at 20KV) and energy dispersive spectrometer (model INCA 250) has been used in the present investigations. A thin layer of gold/ palladium was sputtered on the sample to make it conducting so that high contrast and high resolution images can be recorded. Microstructural features associated with the stone sample were recorded at suitable magnification and areas. Different portions of the stone sample were scanned under the electron beam of SEM in order to observe the variation in the microstructure of the sample. Elemental compositional analysis of the corresponding areas of the stone sample was also carried out by using EDS which is attached to the SEM. Various microstructural features and the element present at different places are presented and described in the present study.

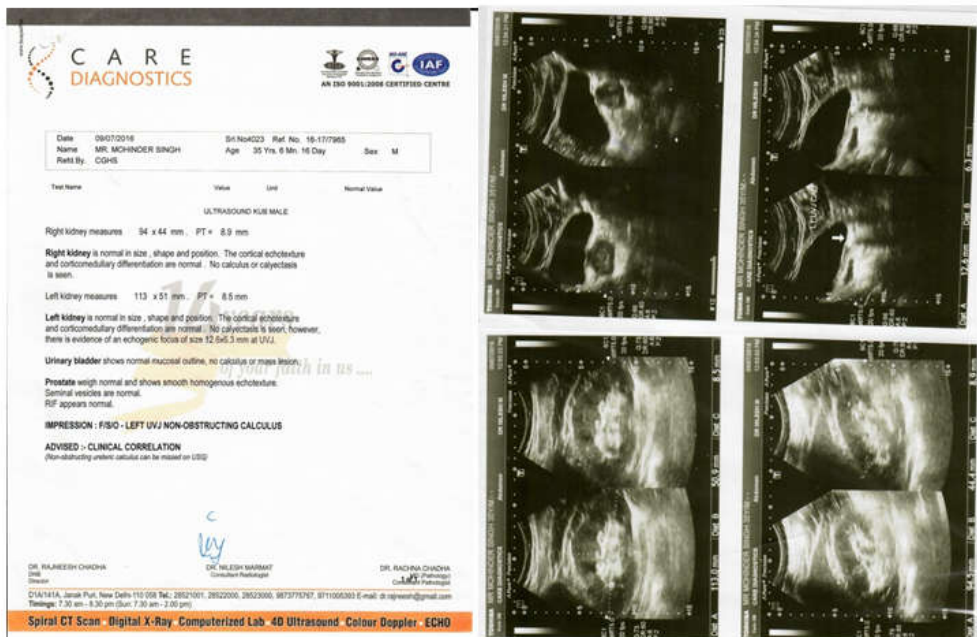

Fig.2 Showing the USG report revealing presence of stone

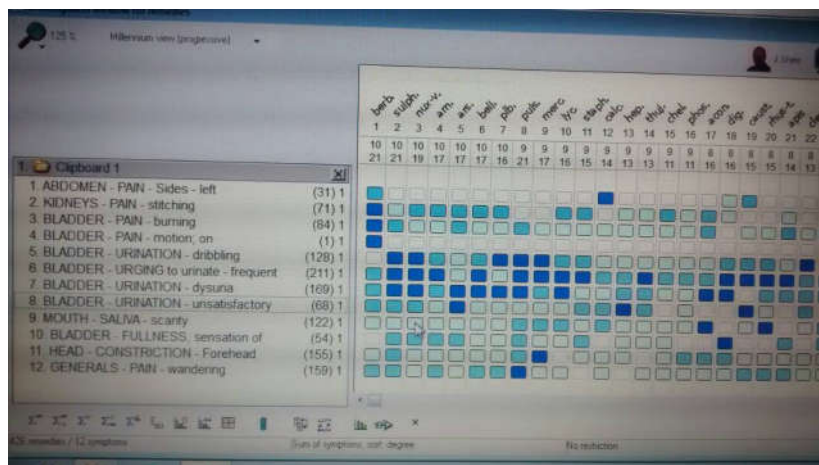


Fig 3: Repertorisation of the case

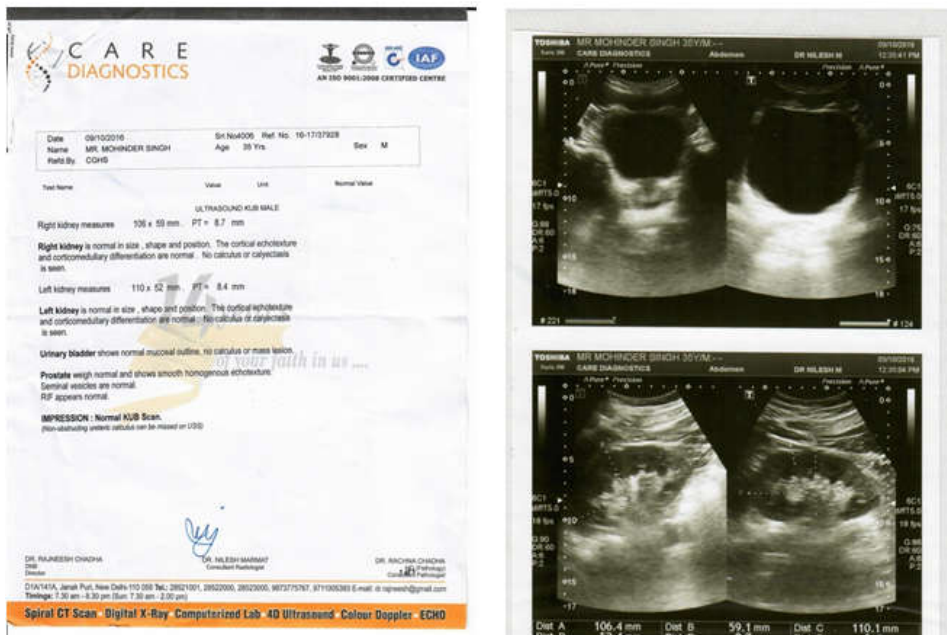

Fig.4. Showing the USG report revealing normal KUB region without any stone

**Follow-ups: The subsequent follow-ups has been summarized in table given below**

Date	Main symptoms/ findings	USG report/ laboratory findings	Prescriptions
July 9, 2016	Pain in the left side of abdomen with rapid change in character, stitching, burning pain, Sensation of constriction on forehead, Urination dribbling by drops, frequent urination, dysuria, painful retention of urine, sensation of fullness of bladder, frequent morbid desire, urging to urinate, Urinary problems aggravated by motion	USG report revealed “Left UV Junction Calculus of size 12.6 X 6.3 mm.” (Fig.2)	Berb. Vul. 30C Twice daily for three days. The patient was advised to increase the water consumption.
July 12, 2016	Pain is mildly reduced but Sensation of constriction on forehead persists. The urinary problems are intermittently present.	Urine microscopical examination shows – Occasional pus cells, epithelial cells 0-2/hpf, RBC 2-3/hpf and calcium oxalate crystals.	Berb. Vul. 30C, continued twice daily for next three days.
July 16, 2016	Though the symptoms are still there, they are reduced in intensity. Feeling better.		Placebo
July 21, 2016	No further improvement	-	Berb Vul 200 Two doses Once daily for two days and Placebo
July 28, 2016	Feeling better	-	Placebo
August 11, 2016	Feeling better	-	Placebo
August 25, 2016	No further improvements		Berb Vul 200 Two doses Once daily for two days and placebo
September 1, 2016	No remarkable changes in the symptoms		Berb Vul 1M Two doses Once daily for two days and placebo
September 22, 2016	A stone passed on September 20, 2016 with mild irritation in the urethra. The patient brought the stone in the OPD.	The stone was measured with normal scale and it was sent for microstructural characterization and elemental analysis	• Placebo • Patient was advised for USG KUB region.
October 13, 2016	No symptoms	The USG – KUB on 9/10/2016 revealed normal scan (Fig.4)	Placebo
October 27, 2016	No symptoms	-	Placebo
November 10, 2016	No symptom	-	Placebo

**Fig.5. Photograph of the stone evolved**

Efforts have been made in order to understand the factors which are responsible for the nucleation and further initiation of the growth of the kidney stone. Surface morphology of the stone sample recorded at different magnifications and the elemental compositional analysis has been shown in Fig.6. SEM image of this area revealed that stone sample comprises of micron sizes smaller stones seems to be agglomerated.

High magnification SEM image as shown in Figure 6(b) revealed that the smaller sizes stones are bonded with nano size fibers which help in the growth of bigger sizes stones. Fig.6 (c) represents the EDS spectra showing presence of different elements present in the same area of the stone sample. Presence of elements in the spectra such as Ca and O are most common and are found in the form of calcium



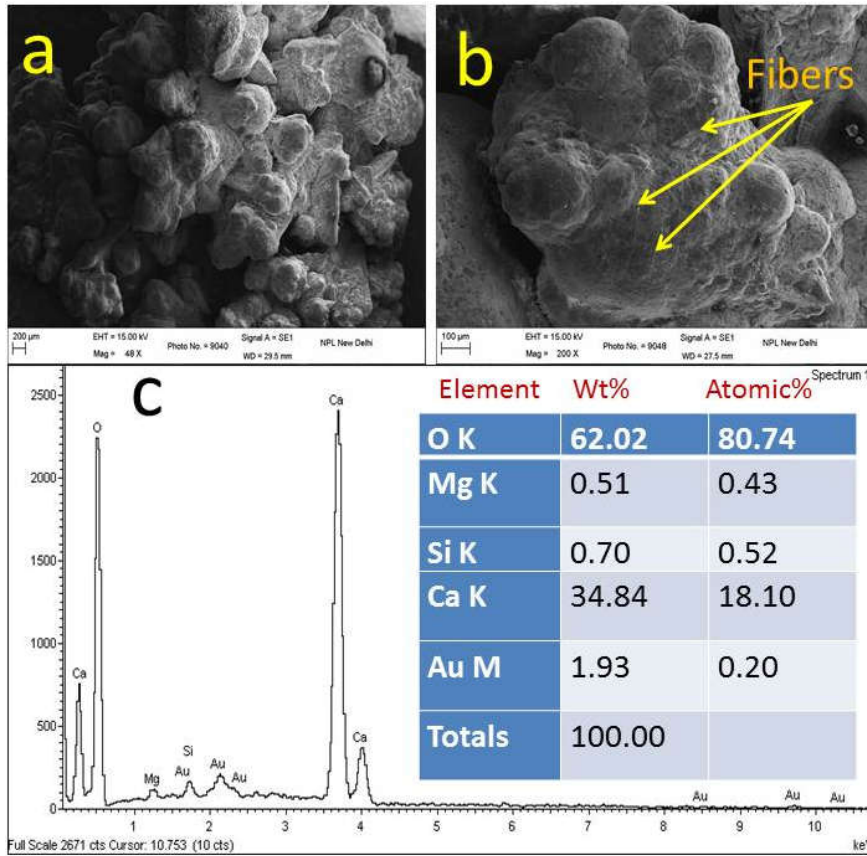


Fig.6 SEM micrographs (a) low magnification image of stone (b) high mag. image showing depicting the presence of some fibers (c) EDS spectra showing presence of different elements of the same area

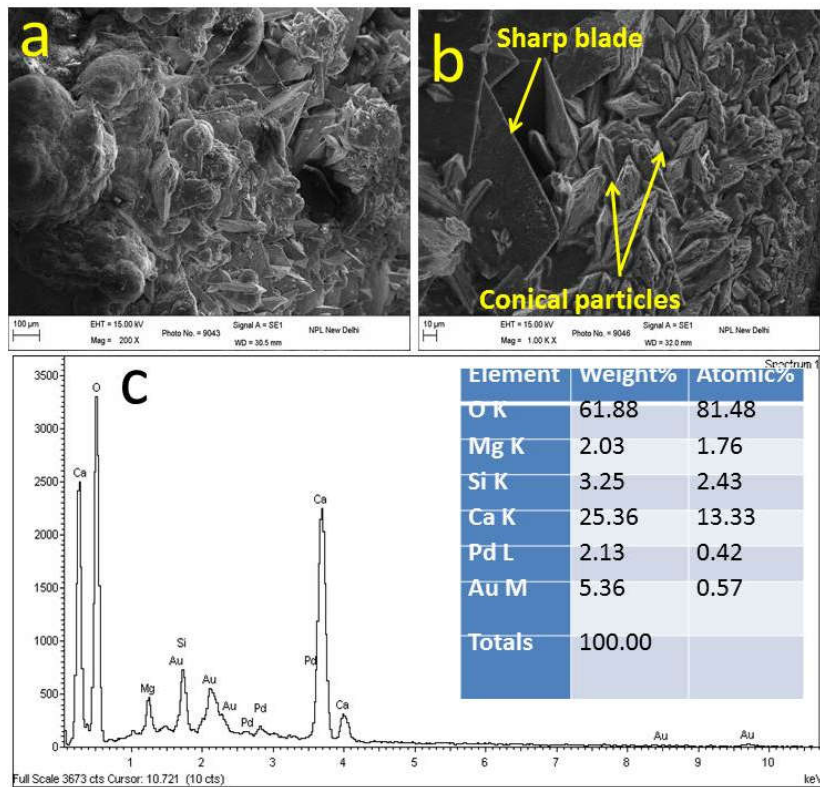
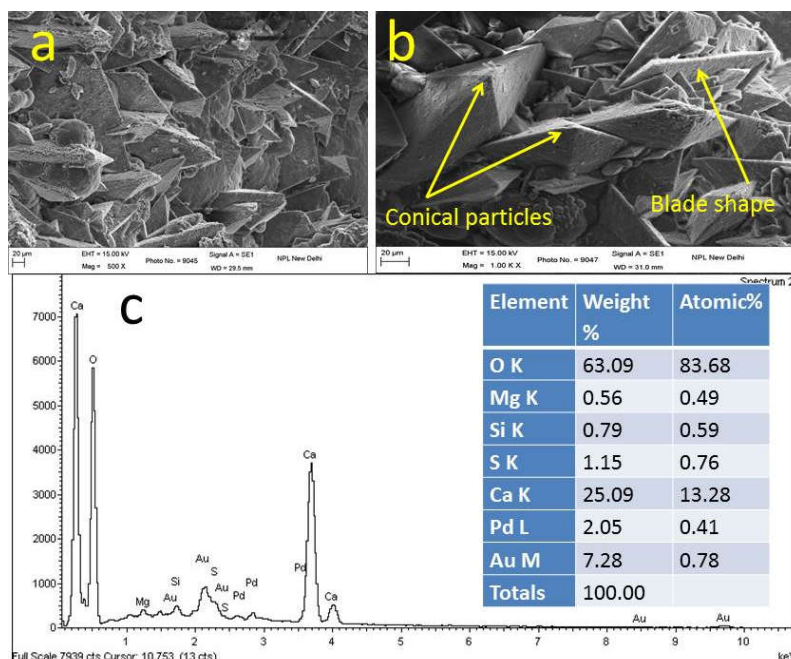


Fig.7 SEM micrographs (a) low magnification image of stone (b) high mag. image revealing sharp blade and conical particles (c) EDS spectra showing presence of different elements of the same area



**Fig.8. SEM micrographs (a) low magnification image of stone (b) high mag. image depicting blade like and conical shape stones (c) EDS spectra of the corresponding area revealing Sulfur also**

oxalates and Mg in the form of struvite. It is important to mention here that the element Si is also found in the stone sample as depicted in the EDS spectra which was never reported earlier. This may be due to the fact that the patient may have been drinking contaminant water or consuming adulterated food for a long time. The presence of Si might have initiated and further helped in the growth of the kidney stone. Existence of Au/Pd in the EDS spectra is due to the thin layer of gold has been deposited on to the stone sample to make it conducting in nature in order to enhance the contrast of the SEM images.

Microstructural features associated with the another area of the stone sample is as shown in Fig.7. SEM image of this area revealed that the stone sample consists of micron and nano sizes smaller stones particles which have different shapes and seems to be agglomerated. High magnification SEM image as shown in Figure 7(b) revealed the presence of sharp blade like formation of kidney stones. Some conical shape particles are also seen in the high magnification image. Sharp blade like and conical shape particles are expected to be responsible for the acute pain in the abdomen. Fig. 7(c) represents the EDS spectra showing presence of different elements present in the same area of the stone sample. As usual, presence of elements in the EDS spectra such as Ca and O are most common and are found in the form of calcium oxalates and Mg in the form of struvite. Presence of Si and Mg is further noticed in the stone with higher percentage as compared to the EDS spectra shown in Fig.6. The presence of Si might have acted as a catalyst in initiating and helped in the further growth of the kidney stone. Large fraction of area of SEM image revealed the presence of sharp blade like and conical shape very tiny stones as shown in Fig.8 (a&b). Surprisingly the presence of S along with elements such as O, Ca, Mg, Si, Au and Pd is also revealed as depicted in the EDS spectra shown in Fig. 8(c). This is important to mention here that Silicon has been found to be present in all the areas of the stone imaged during the present study. The presence of Silicon in the elemental analysis may be the new stone promoter and may be the result of increasing air pollution/ food adulteration/ impure water

supply in the area of Delhi/ NCR. Sulfur may have contributed in the formation of kidney stone from the environmental condition in the city where the patient is located.

**Financial Support and Sponsorship:** Nil

**Conflict of Interest:** There is no conflict of interest.

**Acknowledgements:**

- CSIR-National Physical Laboratory, New Delhi, Govt. of India for their support in the study especially in the elemental analysis of the evolved kidney stone.
- Special thanks to Sh. Mohinder Singh, a patient in the study, for giving his consent to present his case for scientific research for the benefit of the medical science.

## REFERENCES

- Boericke William, Pocket Manual of Homoeopathic Materia Medica & Repertory, B. Jain Publishers Pvt. Ltd., LPE, 10<sup>th</sup> Impression, 119-121.
- Chaudhuri N. M., A Study on Materia Medica, B. 2006. Jain Publishers Pvt. Ltd. Reprint Edition, 168-172.
- Dropkin Benjamin M., Moses Rachel A., Sharma Devang, Pais Vernon M. 2015. The Natural History of Non-obstructing Asymptomatic Renal Stones managed with active surveillance. *The Journal of Urology. American Urological Association* April Vol 193; 1265-69.
- McPhee Stephen J., Papadakis Maxine A., Rabow Michael W. 2012. Current Medical Diagnosis & Treatment; Chapter 23; 922.
- Munjal YP, Sharma SK, Agarwal AK, Gupta P, Kamath SK, Nadkar MY, Singal RK, Sundar S, Varma S et al. 2015. API Textbook of Medicine, 8;1797-1801.
- Phatak S.R. 2011. Materia Medica of Homoeopathic Medicines, Indian Books and Periodicals Publishers, Reprint Edition, October, 102-104.
- Robbin's Basic Pathology; Chapter 14; 571.