



## Full Length Research Article

### CONTEMPORARY IMAGING OF SALIVARY GLANDS

**\*Melek TASSOKER and Sevgi OZCAN**

Department of Oral and Maxillofacial Radiology 42050-Karatay, Konya

#### ARTICLE INFO

##### Article History:

Received 24<sup>th</sup> April, 2016  
Received in revised form  
20<sup>th</sup> May, 2016  
Accepted 10<sup>th</sup> June, 2016  
Published online 31<sup>st</sup> July, 2016

##### Key Words:

CT,  
Imaging,  
MRI,  
Salivary Gland,  
Ultrasound.

Copyright©2016, Melek TASSOKER and Sevgi OZCAN. This is an open access article distributed under the Creative Commons Attribution License, which permits unrestricted use, distribution, and reproduction in any medium, provided the original work is properly cited.

#### ABSTRACT

Parotid, submandibular, and sublingual glands are the major paired salivary glands. Imaging of the salivary glands has an important role in examination of morphology and function, to establish a diagnosis, for treatment, and for surgical planning. There are several options for diagnostic imaging: plain radiography, sialography, ultrasound (US), magnetic resonance imaging (MRI), computed tomography (CT), cone beam computed tomography (CBCT), salivary gland scintigraphy and positron emission tomography (PET). The aim of this paper is to analysis these modalities in conjunction with common salivary gland diseases.

#### INTRODUCTION

The major salivary glands are the parotid glands, located in front of the ear, the sublingual glands, under the tongue, and the submandibular glands, below the mandible, laterally. In addition, there are several small accessory salivary glands in the oral cavity, paranasal sinuses, larynx and pharynx (Afzelius *et al.* 2016). Salivary glands are susceptible to a wide range of disease (Liyanage *et al.* 2007) and sialolithiasis are the most common diseases of the salivary glands (Alkurt and Peker 2009; Bhullar *et al.* 2015; Liyanage *et al.* 2007; Madani and Beale 2006; Rzymska-Grala *et al.* 2010). Imaging has an important role in making a diagnosis and in planning further management, operative or otherwise. Some diseases may overlap and the optimal methods of imaging may change depending on the presentation (Abdullah, Rivas and Srinivasan 2013; Burke *et al.* 2011).

#### Salivary glands imaging includes

- Plain radiography
- Ultrasonography (US)
- Computed tomography (CT)

- Cone beam computed tomography (CBCT)
- Magnetic resonance imaging (MRI)
- Sialography (conventional, CT, MRI)
- Scintigraphy / Positron Emission Tomography (PET)
- Sialendoscopy
- Advanced imaging

#### Plain radiography

This is the simplest, oldest, and cheapest way of studying the salivary glands. It is useful in detecting ductal calculi (Rastogi *et al.* 2012) however, it is failure-susceptible for small or less-calcified calculi especially if superimposed by well-calcified bone, and 10% to 30% of salivary stones are categorized as radiolucent. If a small calculi are present or calculi are superimposed on anatomical structures, a second radiological 2D plane must be performed (Dreiseidler *et al.* 2010). Evaluation of the salivary glands by plain radiography is of limited clinical value (Waseem and Forte 2005). Furthermore, phlebolithiasis, hemangiomas with calcifications or calcified lymph nodes may mimic sialolithiasis on plain radiography (Rastogi *et al.* 2012).

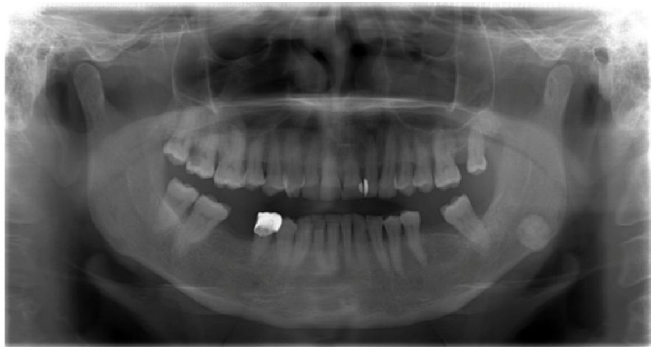**Intraoral radiography:** Sialoliths in the anterior two thirds of the submandibular duct are typically demonstrated with a

**\*Corresponding author: Melek TASSOKER**

Department of Oral and Maxillofacial Radiology 42050-Karatay, Konya.

mandibular occlusal radiograph. The posterior portion of the duct may be imaged with an over-the-shoulder occlusal projection view, where the directing cone is placed on the shoulder and the central ray is directed in an anterior direction through the angle of the mandible, with the patient's head rotated back and tilted to the unaffected side. Parotid sialoliths are more difficult to view than the submandibular variety owing to the tortuous course of Stensen's duct around the anterior border of the masseter and through the buccinator muscle. As a rule, only sialoliths anterior to the masseter muscle can be imaged on an intraoral image. To demonstrate sialoliths in the anterior part of the duct, an intraoral image receptor is stabilized with a holder inside the cheek, as high as possible in the buccal sulcus and over the parotid papilla. The central ray is directed perpendicular to the center of the receptor (White and Pharoah 2014).

**Extraoral radiography:** Panoramic images could be both distorted and magnified, which means that unreliable results could be produced (Miloğlu *et al.* 2010) (Figure 1). They frequently demonstrate sialoliths in the posterior duct or reveals intraglandular sialoliths in the submandibular gland if they are within the focal trough. The image of most parotid sialoliths is superimposed over the ramus and body of the mandible at the level of or just superior to the occlusal plane, making oblique lateral radiographs of the mandible of limited value (White and Pharoah 2014). Parotid glands can be visualized in anterior posterior (AP) projection with extended chin, open mouth and cheeks puffed out to show Stensen's duct lesion. The submandibular gland can be visualized in AP and ipsilateral oblique projections with extended chin, open mouth and the tongue pressed down in the floor of the mouth (Afzelius *et al.* 2016; White and Pharoah 2014).



**Figure 1.** Panoramic radiograph of the patient diagnosed with submandibular sialolithiasis

### Ultrasonography

US is in many cases (especially in children and pregnant women) the initial imaging modality for assessment of the parotid and submandibular glands (Abdullah, Rivas and Srinivasan 2013; Burke *et al.* 2011; Carotti *et al.* 2014). Compared with CT imaging and MRI, US has the following advantages: relatively inexpensive, widely available, painless, easy to perform, no ionizing radiation risk, and noninvasive (White and Pharoah 2014). Using high frequency (7–15 MHz) probes, US has a high spatial and temporal resolution, and a high accuracy for depicting benign and malignant lesions, especially superficial lesions (Gritzmann 1989).

It has limitations in evaluating structures behind bone, that is behind the mandible and the deep parts of the parotid gland (Afzelius *et al.* 2016). The primary applications of US are the differentiation of solid masses from cystic ones and it also aids in guiding the exact side of fine-needle aspiration biopsies in suspected salivary gland lesions (Rastogi *et al.* 2012; White and Pharoah 2014). If a tumour is benign on needle biopsy no further imaging is required. If the tumour affects the deep parotid lobe or potentially extends intracranially, MRI or CT is recommended to depict the tumour (Afzelius *et al.* 2016). US is the least invasive method (Dreiseidler *et al.* 2010) and be used in patients with acute sialadenitis (Miloğlu *et al.* 2010). More recent studies suggest that this technique may also be helpful in diagnosing autoimmune lesions such as Sjögren's syndrome and in detecting sialoliths (White and Pharoah 2014). However, failure has been reported in cases of small semi calcified stones (Dreiseidler *et al.* 2010). In Sjögren's syndrome, the salivary glands become enlarged and heterogeneous. These changes are more pronounced in the parotid gland than in the submandibular gland (Takagi *et al.* 2010). When combined with color Doppler imaging, it helps in assessing the vascularity and nature of the lesion (Taneja *et al.* 2015) (malignant lesions of salivary glands are highly vascular as compared to their benign counterparts) nodal involvement with central vascularity and ill-defined margins are highly indicative of malignant salivary gland lesion (Rastogi *et al.* 2012). In acute viral infection for instance with mumps, the symptoms are usually bilateral and the glands are enlarged and more hypoechoic due to oedema. Increased vascularization using colour Doppler may be seen (Rastogi *et al.* 2012) Necmettin Erbakan University, Faculty of Dentistry.

**Ultrasound elastography:** Elastography was developed in the 1990's to map tissue stiffness, and replaces the palpation performed by clinicians (Gennisson *et al.* 2013). Ultrasound elastography is a method to assess the mechanical properties of tissue, by applying stress and detecting tissue displacement using ultrasound (Drakonaki, Allen and Wilson 2012). Although researchers demonstrated a difference in elastographic score between benign and malignant tumors, it appears to be a limited technique in the differential diagnosis between benign and malignant salivary masses (Dumitriu *et al.* 2011). Larger studies are needed to determine the value of this new method (Celebi and Mahmutoglu 2013; Mansour and Omar 2012).

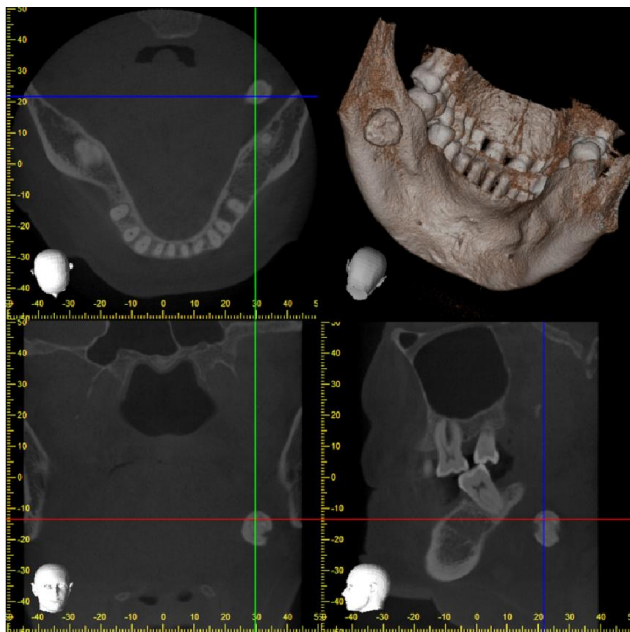
### Computed tomography

CT imaging is useful in evaluating structures in adjacent to the salivary glands, assessing acute inflammatory processes and abscesses, cysts, mucocèles, and neoplasia. It displays both soft and hard tissues and little differences in soft tissue densities (White and Pharoah 2014). It is easy, rapid and cheap compared to MRI (Burke *et al.* 2011) but it involves exposure to ionizing radiation to the head and neck (Afzelius *et al.* 2016). The imaging study is typically assessed in both hard and soft tissue windows. Glandular tissues are usually easily discernible from surrounding fat and muscle. The parotid glands are more radiopaque than the surrounding fat but less opaque than adjacent muscles. Although the submandibular and sublingual glands are similar in density to adjacent muscles, they are readily identified on the basis of shape and location (White and Pharoah 2014).

Unenhanced CT is useful in identifying small calculi within the salivary gland or duct, and is the technique of choice to look for bony erosion caused by malignant lesions. Enhanced CT is used in the staging of malignant disease that involves the salivary glands and chest and can detect regional lymph node metastases and systemic involvement. CT is useful where MRI is contraindicated for evaluation of the deep lobe, and to assess lymphadenopathy of the pharynx and neck. Its use however, should be restricted where possible because of the high dose of radiation involved (Burke *et al.* 2011). CT demonstrates the osseous lesions/extension and calcification/calculus better than MRI but ductal system is not optimally evaluated by any of these two techniques (Rastogi *et al.* 2012).

### Cone Beam Computed Tomography

CBCT provides relatively high isotropic spatial resolution of osseous structures with a lower dose of radiation dose than conventional CT (Miracle and Mukherji 2009a; Miracle and Mukherji 2009b). It is useful in evaluating structures in and adjacent to salivary glands but cannot resolve differences in soft tissue densities. Minimally calcified sialolithiasis is well depicted on CBCT imaging (**Figure 2**), and it is useful as a recording modality for conventional sialography, providing three-dimensional visualization of the ductal structure (White and Pharoah 2014).



**Figure 2. Axial, coronal, sagittal and 3D CBCT reconstructions showing the sialolith (same patient)**

### Magnetic resonance imaging

MRI typically provides a different and superior soft tissue contrast resolution than CT imaging with the advantage of not using ionising radiation; it also results in fewer problems with streak artifacts from metallic dental restorative materials (Burke *et al.* 2011; White and Pharoah 2014). Pacemaker, implanted metals, claustrophobia, long acquisition time and the cost are all disadvantages (Afzelius *et al.* 2016; Burke *et al.* 2011). It is important in evaluation of major salivary gland diseases, especially neoplastic diseases.

Infiltration into the parapharyngeal space, muscles or bone will strongly suggest malignancy (Freling *et al.* 1992). If there is a strong suspicion of malignancy, MRI is the method of choice (Yousem *et al.* 2000). It allows for the assessment of perineural spread of malignant tumours, deep lobe extension, or meningeal infiltration that is not possible with US (Barakos *et al.* 1991; Parker and Harnsberger 1991). Skull base invasion is often well seen by MRI (Freling 1994). Of all available methods of imaging MRI offers the best visualisation of the facial nerve (Takahashi *et al.* 2005). If the tumour is large (>3 cm) or located in the deep lobe of the parotid gland, US has limitations in demonstrating and delineating the lesions sufficiently, and MRI (or CT when contraindications to MRI exist) should be performed (Afzelius *et al.* 2016). MRI can be an alternative to conventional sialography in evaluating ductal pathosis, especially when ductal catheterization is either problematic or contraindicated (White and Pharoah 2014). MRI is also useful when used for disorders that mimic parotid swelling, for example in apparent diffuse parotid swelling that may be caused by hypertrophy of the muscles of mastication (Burke *et al.* 2011). If the indications for CT imaging and MRI overlap, MRI should be chosen in evaluating parenchymal masses or cystic lesions because of superior display of salivary gland masses, internal structures, and regional extension of the lesions into adjacent tissues or spaces, especially in examining the submandibular glands (White and Pharoah 2014).

### Sialography

Conventional X-ray sialography was first mentioned by Carpy in 1902 (Afzelius *et al.* 2016; Raj *et al.* 2016; White and Pharoah 2014) using mercury as the contrast medium (Raj *et al.* 2016). Sialography is considered the gold standard-most detailed technique for studying the ductal morphology (Rastogi *et al.* 2012; White and Pharoah 2014). CBCT (Miloğlu *et al.* 2010), CT and US (Waseem and Forte 2005) have shown to be of limited value in visualizing the ductal system. Sialography technique requires injecting contrast media into the Stensen's or Wharton's duct of the major salivary glands to identify the outline of the ductal anatomy and any presence of sialoliths (Burke *et al.* 2011). Sialography is rarely used for sublingual imaging because of numerous, usually 20, small ducts of Rivinius opening directly into the floor of mouth making an overview difficult (Afzelius *et al.* 2016; Rastogi *et al.* 2012).

Sialography has up to 100% diagnostic accuracy (Miloğlu *et al.* 2010) and creates excellent contrast resolution and allows small stones or strictures to be detected (Burke *et al.* 2011). However its use is contraindicated in patients who are having contrast allergy (Kuruvila *et al.* 2013), acute infections and orifice stones (Miloğlu *et al.* 2010). Other complications include rupture of the ductal system and activation of clinically dormant infection (Afzelius *et al.* 2016). Its main indication is chronic sialadenitis unrelated to sialolithiasis (Rastogi *et al.* 2012). Conventional sialography uses panoramic, occlusal, and posteroanterior radiographs (Waseem and Forte 2005). In addition to static projection radiographic images, the opacified gland can be imaged with CBCT, CT (White and Pharoah 2014) and MRI with use of heavily T2-weighted sequences (Kalinowski *et al.* 2002). MR sialography depicts the ductal system of the gland without injection of ductal/intravenous contrast and can be performed in patients of

acute sialadenitis. Patient's own saliva is used as contrast agent. The administration of a sialogogue (lemon juice or similar) may improve ductal visualization in MR sialography by increasing salivary secretion (Hugill *et al.* 2008; Jager *et al.* 2000). It requires sufficient production of saliva (Afzelius *et al.* 2016). MR sialography has poor spatial resolution as compared to conventional sialography (Kalinowski *et al.* 2002) but may be an alternative if x-ray sialography cannot be performed (Uddin 2012).

### Scintigraphy / PET

Nuclear medicine can be used to study salivary gland function (Burke *et al.* 2011; White and Pharoah 2014). It is a rarely used technique for salivary gland imaging (Rastogi *et al.* 2012). All major salivary glands can be studied at once (White and Pharoah 2014). Scintigraphy has been used to examine the presence and extent of the oral involvement in Sjögren's syndrome and may also be helpful for prediction of the salivary gland function following radiation therapy (Tenhunen *et al.* 2008). Scintigraphy cannot be used for differentiation between benign and malignant tumours, nor can it predict the outcome of a surgical procedure (Afzelius *et al.* 2016). Despite a much greater resolution than scintigraphy, PET has not been useful for classifying salivary tumors as benign or malignant (Roh *et al.* 2007; White and Pharoah 2014).

### Sialendoscopy

Sialendoscopy has been used as both a diagnostic and an interventional modality (Al-Abri and Marchal 2010; Arslan *et al.* 2015). This procedure allows to visualise the lumen of the salivary ducts and their pathologies and provides the complete exploration of the salivary ductal system. It is positioned to replace sialography and other radiological studies because of its higher specificity and cost-effectiveness (Al-Abri and Marchal 2010). The first reported attempts to visualise the ducts were conducted in the early 1990s (Gundlach, Hopf and Linnarz 1994; Katz 1991). Diagnostic sialendoscopy was used to classify ductal lesions into sialolithiasis, stenosis, sialodochitis, and polyps. Interventional sialendoscopy is used to treat disorders discovered during diagnostic sialendoscopy. As the most frequent ductal pathology is sialolithiasis, interventional sialendoscopy aims to retrieve salivary stones following their fragmentation (Al-Abri and Marchal 2010).

### Advanced imaging

Recently, new MRI techniques, such as dynamic contrast enhanced MRI (DCE-MRI), diffusion-weighted MRI (DW-MRI), and proton MRI spectroscopy, have shown promising results in the differentiation between benign and malignant salivary gland tumors (Abdullah, Rivas and Srinivasan 2013). However, these techniques are not routinely used in daily clinical practice and will only be briefly mentioned in this review.

### Conclusion

- US is the least invasive method and should be the first line modality but it has limitations in evaluating

structures behind bone and the deep parts of the parotid gland.

- CT and CBCT are useful in detection of calculi and bony involvement, however CT use is limited by the high dose of radiation involved. CT has an advantage of both displaying soft and hard tissues.
- MRI, due to its excellent soft tissue contrast, is the preferred modality differentiating benign from malignant lesions. If there is a strong suspicion of malignancy, MRI is the method of choice.
- Sialography remains the gold standard for the assessment of suspected ductal calculi or strictures.

### REFERENCES

- Abdullah, A., Rivas, F. F. and Srinivasan, A. 2013. "Imaging of the salivary glands." *Semin Roentgenol* 48(1):65-74.
- Afzelius, P., Nielsen, M. Y., Ewertsen, and K. P. Bloch, C. 2016. "Imaging of the major salivary glands." *Clin Physiol Funct Imaging* 36(1):1-10.
- Al-Abri, Rashid, and Francis Marchal. 2010. "New era of Endoscopic Approach for Sialolithiasis: Sialendoscopy." *Sultan Qaboos University Medical Journal* 10(3):382-87.
- Alkurt, M. T., and I. Peker. 2009. "Unusually Large Submandibular Sialoliths: Report of Two Cases." *Eur J Dent.*, 3(2):135-39.
- Arslan, S., Vuralkan, E., Cobanog Lu, B., Arslan, A. and Ural, A. 2015. "Giant sialolith of submandibular gland: report of a casedagger." *J Surg Case Rep.*, 2015(4).
- Barakos, J. A., Dillon, W. P. and Chew, W. M. 1991. "Orbit, skull base, and pharynx: contrast-enhanced fat suppression MR imaging." *Radiology*, 179(1):191-98.
- Bhullar, R. S., Dhawan, A., Bhullar, K. and Malhotra, S. 2015. "Giant submandibular gland duct sialolith mimicking an impacted canine tooth." *Natl J Maxillofac Surg.*, 6(1):89-92.
- Burke, C. J., Thomas, R. H. and Howlett, D. 2011. "Imaging the major salivary glands." *Br J Oral Maxillofac Surg.*, 49(4):261-9.
- Carotti, M., Ciapetti, A., Jousse-Joulin, S. and Salaffi, F. 2014. "Ultrasonography of the salivary glands: the role of grey-scale and colour/power Doppler." *Clin Exp Rheumatol* 32(1 Suppl 80):S61-70.
- Celebi, I. and Mahmutoglu, A. S. 2013. "Early results of real-time qualitative sonoelastography in the evaluation of parotid gland masses: a study with histopathological correlation." *Acta Radiol* 54(1):35-41.
- Drakonaki, E. E., Allen, G. M. and Wilson, D. J. 2012. "Ultrasound elastography for musculoskeletal applications." *Br J Radiol* 85(1019):1435-45.
- Dreiseidler, T., Ritter, L., Rothamel, D., Neugebauer, J., Scheer, M. and Mischkowski, R. A. 2010. "Salivary calculus diagnosis with 3-dimensional cone-beam computed tomography." *Oral Surg Oral Med Oral Pathol Oral Radiol Endod.*, 110(1):94-100.
- Dumitriu, D., Ducea, S., Botar-Jid, C., Baciut, M. and Baciut, G. 2011. "Real-time sonoelastography of major salivary gland tumors." *AJR Am J Roentgenol* 197(5):W924-30.
- Freling, N. J. 1994. "[Imaging of the salivary glands. CT and MRI]." *Radiologe* 34(5):264-72.

- Freling, N. J., Molenaar, W. M., Vermey, A., Mooyaart, E. L. Panders, A. K., Annys, A. A. and Thijn, C. J. 1992. "Malignant parotid tumors: clinical use of MR imaging and histologic correlation." *Radiology* 185(3):691-6.
- Gennisson, J. L., Deffieux, T., Fink, M. and Tanter, M. 2013. "Ultrasound elastography: principles and techniques." *Diagn Interv Imaging* 94(5):487-95.
- Gritzmann, N. 1989. "Sonography of the salivary glands." *American Journal of Roentgenology* 153(1):161-66.
- Gundlach, P., Hopf, J. and Linnarz, M. 1994. "Introduction of a new diagnostic procedure: salivary duct endoscopy (sialendoscopy) clinical evaluation of sialendoscopy, sialography, and X-ray imaging." *Endosc Surg Allied Technol* 2(6):294-6.
- Hugill, J., Sala, E. Hollingsworth, K. G. and Lomas, D. J. 2008. "MR sialography: the effect of a sialogogue and ductal occlusion in volunteers." *Br J Radiol* 81(967):583-6.
- Jager, L., Menauer, F., Holzkecht, N., Scholz, V., Grevers, and M. Reiser. 2000. "Sialolithiasis: MR sialography of the submandibular duct--an alternative to conventional sialography and US?" *Radiology* 216(3):665-71.
- Kalinowski, M., J. T. Heverhagen, E. Rehberg, K. J. Klose, and H. J. Wagner. 2002. "Comparative study of MR sialography and digital subtraction sialography for benign salivary gland disorders." *AJNR Am J Neuroradiol* 23(9):1485-92.
- Katz, P. 1991. "[Endoscopy of the salivary glands]." *Ann Radiol (Paris)* 34(1-2):110-3.
- Kuruvila, Vikas Elias, N. Bilahari, Beena Kumari, and Biju James. 2013. "Submandibular sialolithiasis: Report of six cases." *Journal of Pharmacy & Bioallied Sciences* 5(3):240-42.
- Liyanage, S. H., Spencer, S. P. Hogarth, K. M. and Makdiss, J. 2007. "Imaging of salivary glands." *Imaging* 19(1):14-27.
- Madani, G. and T. Beale. 2006. "Inflammatory conditions of the salivary glands." *Semin Ultrasound CT MR* 27(6):440-51.
- Mansour, S. M., and Omar, O. S. 2012. "Elastography ultrasound and questionable breast lesions: does it count?" *Eur J Radiol* 81(11):3234-44.
- Miloğlu, Ö., Çağlayan, F., Ezmeci, T., Dağistan, S. and Demirtaş, Ö. 2010. "Multiple cases of submandibular sialolithiasis detected by cone beam computed tomography." *J Dent Fac Atatürk Uni* 20(3):189-93.
- Miracle, A. C. and Mukherji, S. K. 2009a. "Conebeam CT of the head and neck, part 1: physical principles." *AJNR Am J Neuroradiol* 30(6):1088-95.
- . 2009b. "Conebeam CT of the head and neck, part 2: clinical applications." *AJNR Am J Neuroradiol* 30(7):1285-92.
- Parker, G. D. and Harnsberger, H. R. 1991. "Clinical-radiologic issues in perineural tumor spread of malignant diseases of the extracranial head and neck." *RadioGraphics* 11(3):383-99.
- Raj, P. R., Rawther, N. N., Nausheen, E., Abraham, M. A. and George, G. B. 2016. "Sialography – A Case Report." *IOSR-JDMS* 15(2):67-70.
- Rastogi, R., Bhargava, S., Mallarajapatna, G. J. and Singh, S. K. 2012. "Pictorial essay: Salivary gland imaging." *Indian J Radiol Imaging* 22(4):325-33.
- Roh, J. L., Ryu, C. H., Choi, S. H., Kim, J. S., Lee, J. H., Cho, K. J., Nam, S. Y. and Kim, S. Y. 2007. "Clinical utility of 18F-FDG PET for patients with salivary gland malignancies." *J Nucl Med* 48(2):240-6.
- Rzyska-Grala, Iwona, Zygmunt Stopa, Bartłomiej Grala, Marek Gołębiowski, Hubert Wanyura, Anna Zuchowska, Monika Sawicka, and Michał Zmorzyński. 2010. "Salivary gland calculi – contemporary methods of imaging." *Polish Journal of Radiology* 75(3):25-37.
- Takagi, Y., Kimura, Y., Nakamura, H., Sasaki, M., Eguchi, K. and Nakamura, T. 2010. "Salivary gland ultrasonography: can it be an alternative to sialography as an imaging modality for Sjogren's syndrome?" *Ann Rheum Dis* 69(7):1321-4.
- Takahashi, N., Okamoto, K., Ohkubo, M. and Kawana, M. 2005. "High-resolution magnetic resonance of the extracranial facial nerve and parotid duct: demonstration of the branches of the intraparotid facial nerve and its relation to parotid tumours by MRI with a surface coil." *Clin Radiol* 60(3):349-54.
- Taneja, A., Sachdev, I. S., Sethi, S. and Garga, U. C. 2015. "Salivary gland imaging: A pictorial essay." *Int J Med and Dent Sci* 4(1):692-700.
- Tenhunen, Mikko, Juhani Collan, Mauri Kouri, Aki Kangasmäki, Jorma Heikkinen, Kalevi Kairemo, Antti Mäkitie, Heikki Joensuu, and Kauko Saarilahti. 2008. "Scintigraphy in prediction of the salivary gland function after gland-sparing intensity modulated radiation therapy for head and neck cancer." *Radiotherapy and oncology : journal of the European Society for Therapeutic Radiology and Oncology* 87(2):260-67.
- Uddin, S. M. 2012. "Does MR Sialography Have A Greater Diagnostic Accuracy Than Conventional X-Ray And Digital Subtraction Sialography In Detecting Salivary Glands Disease? A Literature Review." *Nepalese Journal of Radiology; Vol 1, No 1 (2011)*.
- Waseem, Z. and V. Forte. 2005. "An unusual case of bilateral submandibular sialolithiasis in a young female patient." *Int J Pediatr Otorhinolaryngol* 69(5):691-4.
- White, S. C. and Pharoah, M. J. 2014. *Oral Radiology Principles and Interpretation*. St. Louis: Mosby Elsevier.
- Yousem, D. M., Kraut, M. A. and Chalian A. A. 2000. "Major salivary gland imaging." *Radiology* 216(1):19-29.

\*\*\*\*\*