



ISSN: 2230-9926


Available online at <http://www.journalijdr.com>

# IJDR

International Journal of Development Research

Vol. 12, Issue, 11, pp. 60140-60144, November, 2022

<https://doi.org/10.37118/ijdr.25695.11.2022>



RESEARCH ARTICLE

OPEN ACCESS

## ANATOMICAL ANALYSIS OF LINGUAL FORAMINA IN BRAZILIAN INDIVIDUALS USING CONE-BEAM COMPUTED TOMOGRAPHIC IMAGES

Idalísio Soares Aranha Neto<sup>1\*</sup>, Danielle Carvalho Oliveira Coutinho<sup>2</sup>, Pedro César Resende de Assis<sup>3</sup>, Isabela de Castro Ribeiro<sup>4</sup>, Rafael Pereira da Mata Santos<sup>5</sup>, Bruno César Ladeira Vidigal<sup>1</sup>, Paulo Anônio Martins-Júnior<sup>6</sup>, Amaro Ilídio Vespasiano Silva<sup>1</sup>, Flávio Ricardo Manzi<sup>1</sup> and Micena Roberta Miranda Alves e Silva<sup>7</sup>

<sup>1</sup>PhD, Professor, Department of Dentistry, Pontifical Catholic University of Minas Gerais, Belo Horizonte, MG, Brazil; <sup>2</sup>PhD, Post-Doc Researcher, Department of Biochemistry and Immunology, Biological Sciences Institute, Federal University of Minas Gerais, Belo Horizonte, MG, Brazil; <sup>3</sup>Undergraduate, Department of Morphology, Biological Sciences Institute, Federal University of Minas Gerais, Belo Horizonte, MG, Brazil; <sup>4</sup>Undergraduate, Department of Dentistry, Pontifical Catholic University of Minas Gerais, Belo Horizonte, MG, Brazil; <sup>5</sup>DDS, Post-Graduate Student, Department of Dentistry, Pontifical Catholic University of Minas Gerais, Belo Horizonte, MG, Brazil; <sup>6</sup>PhD, Professor, Department of Child and Adolescent Oral Health, Federal University of Minas Gerais, Belo Horizonte, MG, Brazil; <sup>7</sup>PhD, Professor, Department of Morphology, Biological Sciences Institute, Federal University of Minas Gerais, Belo Horizonte, MG, Brazil

### ARTICLE INFO

#### Article History:

Received 02<sup>nd</sup> September, 2022

Received in revised form

17<sup>th</sup> September, 2022

Accepted 29<sup>th</sup> October, 2022

Published online 30<sup>th</sup> November, 2022

#### Key Words:

Radiology; Anatomy; Cone beam computed tomography; Lingual Foramen.

#### \*Corresponding author:

Idalísio Soares Aranha Neto

### ABSTRACT

**Background:** This retrospective study evaluated the anatomic characteristics of lingual foramina and described their possible anatomic variations in a Brazilian sample. **Material and methods:** Linear measurements of the lingual foramina were carried out in the coronal and axial sections of cone beam computed tomography (CBCT) images from 98 Brazilian patients using the RadiAnt DICOM 2.2.9 Viewer<sup>®</sup> software. The mean age of the sample was 54.7 ±13.89 years. The patients were classified into: completely dentate (n=17), edentulous (n=17) and partially edentulous (n=64). **Results:** The CBCT images revealed the presence of 216 foramina on the lingual surface in the anterior region of the mandible. Most patients (n=40; 40.8%) had 2 lingual foramina and most of them were found in the mandible symphysis region (60.6%). There was significant differences in the measurements of the lingual foramina in male and female patients in some regions (p<0.05). Important features and anatomical aspects of the mandibular bone structure were found in relation to the lingual foramina and between male and female patients. **Conclusions:** Dental professionals should draw attention to the need of careful planning and accurate execution of surgical procedures on the lingual surface of the anterior mandible.

Copyright © 2022, Idalísio Soares Aranha Neto et al. This is an open access article distributed under the Creative Commons Attribution License, which permits unrestricted use, distribution, and reproduction in any medium, provided the original work is properly cited.

**Citation:** Idalísio Soares Aranha Neto, Danielle Carvalho Oliveira Coutinho, Pedro César Resende de Assis, Isabela de Castro Ribeiro, et al. 2022. "Anatomical analysis of lingual foramina in brazilian individuals using cone-beam computed tomographic images", *International Journal of Development Research*, 12, (11), 60140-60144.

## INTRODUCTION

The anterior mandibular region (interforaminal) is important for surgical planning, implant installation and serves as a basis for the neurovascular bedding. Treatment planning with dental implants and surgeries in the anterior region is often complicated by the unknown extension of the anterior loop of the neurovascular bundle. In this context, analysis on the bone structure may inform about the course and the difference on the neurovascular bundle. With the advancement of Implant Dentistry, greater attention has been paid to the bony structures that may have an influence on the treatment proposed to patients.

Some of these structures, denominated lingual foramina, are small orifices that may be distributed throughout the lingual surface of the mandibular body, which should be considered in clinical planning because they allow the passage of important neurovascular bundles. When present in the anterior and lingual regions of the mandible, these orifices may be distributed above or below the superior genial spine; or they may be situated in positions lateral to the mandibular symphysis on both the right and left sides<sup>1,2,3</sup>. Studies have revealed that various important structures may cross these foramina, such as the ramus of the sublingual artery and submental artery<sup>4</sup>, in addition to branches of the mylohyoid nerve<sup>5</sup>. Different studies in various populations have revealed that knowledge about these anatomic structures by means of prevalence data; linear measurements

(distance of foramina in relation to the base of the mandible; distance of foramina in relation to the alveolar process; distance in relation to the vestibular cortical bone, distance in relation to the lingual cortical and length of these canals); region of greater incidence (right or left side) are relevant data to the action of dental surgeons in procedures on the lingual surface of the anterior region of the mandible<sup>6</sup>. However, in Brazilian population, the scarce studies are restricted to accessory foramina close to the mental foramen<sup>7,8</sup>. Nevertheless, the description of the bone repairs in the anterior region of the lingual surface of the mandible and other associated variables, such as age, gender, presence/absence of teeth still require an improved approach. In this connection, identifying these structures by means of cone beam computed tomography (CBCT) will not only allow professionals to achieve adequate planning and a better visualization of these structures resulting from better quality of the images, but will also reduce interurrences such as unwanted bleeding, or even changes in sensitivity in the region. Therefore, the aim of this study was to evaluate anatomic characteristics of lingual foramina and describe their possible anatomic variations in a sample of Brazilian sample.

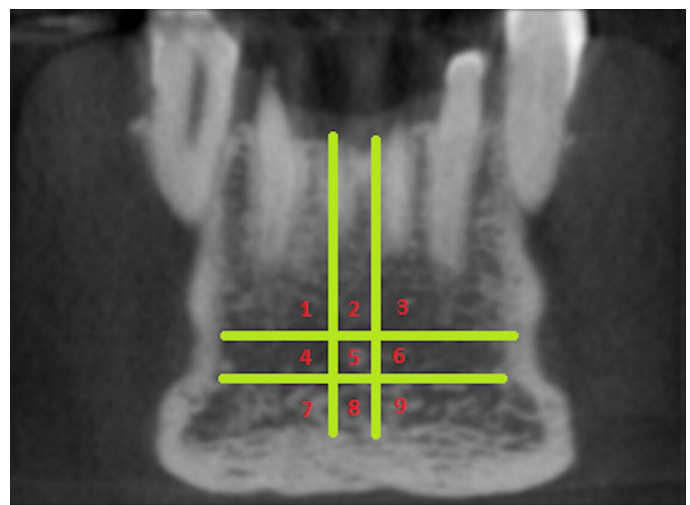## MATERIALS AND METHODS

**Study Sample:** This study was approved by the Human Research Ethics Committee of the Federal University of Minas Gerais (CAAE-40961315.0.0000.5137). This was a retrospective research conducted were carried out in the coronal and axial image of cone beam computed tomography (CBCT) (CBCT - CS 8100 Carestream Health®, Inc., Atlanta, GA, USA) images from 98 adult patients from the database of a private practice in Belo Horizonte, Brazil. The selected images were evaluated under lighting conditions that were adequate for tomographic assessments, without identifying the individuals. Inclusion criteria were those images from adult patients that allowed a complete visualization of the lingual surface in the anterior region of the mandible. Images with inadequate visualization of the lingual foramina, and of individuals under the age of 18 years were not considered.

**Study Variables:** In CBCT exams, the images of mandibles were reconstructed respecting the correct anatomic position in relation to the median sagittal plane and in relation to the Frankfurt plane with the patient in occlusion, thus seeking to standardize all the examinations performed as well as the images before selecting the cuts for measurement.<sup>3</sup> After careful analysis of the CBCT images (CBCT - CS 8100 Carestream Health®, Inc., Atlanta, GA, USA), by using RadiAnt DICOM 2.2.9 Viewer® software (Medixant 2.2.9, Poznan, Poland), lingual foramina were identified and then, classified according to the region of occurrence, as follows: superior, middle and inferior to the genial spine in the mandibular symphysis were called midline lingual foramina (corresponding to positions 2, 5, 8); foramina located laterally were called lateral lingual foramina (corresponding to positions 1, 4, 7 – left side) and (corresponding to positions 3, 6, 9 – right side). It is noteworthy that the foramina present in regions 1, 2 and 3 were those located superior to the genial spine up to the alveolar crest. The regions of the lingual surface of the anterior region were divided into nine quadrants to facilitate localization of the foramina to determine their localization (Fig 1).

The frequency and number of the lingual foramina were analyzed. Linear measurements of the lingual foramina were carried out by using RadiAnt DICOM 2.2.9 Viewer® software (Medixant 2.2.9, Poznan, Poland) and included vestibular and lingual heights of the canals in relation to the mandibular base, respective diameters of the foraminal openings and bony canal endings, and lengths of the canals.<sup>3</sup> The measurements were performed by a single, trained, calibrated and experienced examiner, who obtained Kappa values of 0.9 for inter-examiner agreement, which was considered excellent. Besides that, the linear measurements (mm) (Fig 2) were carried out and were identified by letters from A to F, as follows:

- A. Vertically plotted linear measure measuring the distance from the mental foramen (canal entrance) to the cortical of the base of the mandible;
- B. Linear measurement drawn vertically from the foramen (canal entrance) to the region corresponding to the height of the alveolar bone crest of the mandible;
- C. Horizontal linear measurement drawn from the inner end of the canal to the cortical of the base of the mandible;
- D. Linear measurement taken on the inside of the canal (foramen) in the most centralized region of the canal viewed on the tomographic section to the most posterior region of the outside of the canal entrance;
- E. Vertically plotted linear measurement with the distance from the inner part of the canal (foramen) in the most centralized region of the canal to the outer part of the base of the mandible;
- F. Vertically plotted linear measurement with the distance from the inner part of the canal (foramen) in the most centralized region of the canal to the region corresponding to the height of the alveolar bone crest of the mandible.



**Figure 1. Classification of lingual foramina according to their localization in the anterior region of the lingual surface of the mandible**

**Data Analysis:** The data were digitalized and organized in the *Statistical Package for Social Sciences* (SPSS for Windows®, version 20.0, SPSS Inc. Chicago, Ill, USA). The statistical analysis involved the distribution of frequencies of lingual foramina and tests of association. The chi-square test was used to compare the variables age, side of foramina and type of dentition between males and females. In addition, the Kolmogorov-Smirnov normality test was performed to verify the normality of data distribution. According to the results, the independent samples t-test or Mann-Whitney test were used to analyze linear measurements. The significance level was set at 5% ( $P < .05$ ).

## RESULTS

The age of the patients ranged between 21-91 years with a mean of  $54.7 \pm 13.89$  years. Of the 98 patients, 68 (69.4%) were females. Most of the patients were partially edentulous ( $n = 64$ ; 65.3%). The CBCT images revealed the presence of 216 foramina on the lingual surface in the anterior region of the mandible. Besides that, 24 (24.5%) patients had only one lingual foramen in the region of the mandible; 40 (40.8%) patients had two lingual foramina; 25 (25.5%) individuals had three lingual foramina; eight (8.1%) patients had four foramina and only one (1.02%) had five lingual foramina in the anterior region of the lingual surface of the mandibular body. The present study revealed that the region in which the presence of lingual foramen was most common was Region 2 (31.9%) of the internal surface of the mandible.

**Table 1 Analysis of distribution of foramina, considering sex with regard to parameters: age, side and dentition.**

Variables	Sex		P*
	Male n (%)	Female n (%)	
Age			
Between 21 and 57 years	40 (34.5)	76 (65.5)	.006
Between 58 and 91 years	18 (18.0)	82 (82.0)	
Side			
Symphysis	36 (27.5)	95 (72.5)	.349
Right	9 (19.6)	37 (80.4)	
Left	13 (33.3)	26 (66.7)	
Dentition			
Complete	5 (29.4)	12 (70.6)	.580
Partially Complete	18 (28.1)	46 (71.9)	
Edentulous	7 (41.2)	10 (58.8)	

**Table 2. Data obtained for lingual foramina variables relative to gender A- Distance from foramen (canal entrance) up to base of the mandible; B- Distance from foramen (canal entrance) up to the alveolar bone crest; C- Distance from end of the canal up to the vestibular cortical bone; D- Length of canal; E- Distance from end of the canal up to the base of the mandible; F- Distance from end of the canal up to the alveolar bone crest. Measurements are displayed in mm**

Measurements	Mean (SD)	Median (25 <sup>th</sup> -75 <sup>th</sup> )	Range	P
A	8.08 (3.53)	8.15 (5.00-10.87)	2.29-16.20	.441 <sup>a</sup>
Male	7.62 (4.08)	7.73 (4.63-10.01)	1.48-23.40	
Female				
B	19.64 (6.74)	19.55 (15.67-23.82)	3.22-35.40	.201 <sup>b</sup>
Male	17.80 (6.38)	18.35 (13.67-22.65)	1.38-28.60	
Female				
C	6.72 (2.03)	6.58 (4.78-8.38)	1.91-10.10	.931 <sup>b</sup>
Male	6.69 (1.93)	6.77 (5.17-8.01)	2.88-12.10	
Female				
D	6.34 (2.64)	5.37 (4.31-8.05)	3.06-14.00	.126 <sup>a</sup>
Male	5.37 (2.02)	5.20 (3.63-6.44)	2.45-10.90	
Female				
E	8.81 (2.86)	8.78 (6.38-11.10)	3.62-14.80	.724 <sup>b</sup>
Male	8.56 (3.40)	7.92 (5.98-10.75)	3.33-21.70	
Female				
F	20.77 (6.58)	21.30 (18.07-23.95)	4.21-32.30	.291 <sup>a</sup>
Male	18.83 (6.30)	20.25 (15.52-23.02)	2.07-29.40	
Female				

<sup>a</sup>Mann-Whitneytest, <sup>b</sup>t-test**Table 3. Analysis of lingual foramen variables in relation to their regions of localization**

Measurements	Regionsof lingual foramina								
	1	2	3	4	5	7	8	9	
A	.736 <sup>a</sup>	.650 <sup>a</sup>	.820 <sup>a</sup>	.737 <sup>a</sup>	.860 <sup>a</sup>	.322 <sup>a</sup>	.971 <sup>a</sup>	.272 <sup>b</sup>	
B	.095 <sup>a</sup>	.087 <sup>b</sup>	.743 <sup>a</sup>	.769 <sup>a</sup>	.060 <sup>a</sup>	.571 <sup>a</sup>	.050 <sup>a</sup>	.665 <sup>b</sup>	
C	.256 <sup>a</sup>	.160 <sup>b</sup>	.681 <sup>a</sup>	.189 <sup>a</sup>	.696 <sup>a</sup>	.093 <sup>a</sup>	.281 <sup>a</sup>	.154	
D	.989 <sup>a</sup>	.557 <sup>a</sup>	.364 <sup>a</sup>	.725 <sup>a</sup>	.722 <sup>a</sup>	.350 <sup>a</sup>	.162 <sup>a</sup>	.009 <sup>b</sup>	
E	.787 <sup>a</sup>	.052 <sup>a</sup>	1.000 <sup>b</sup>	.832 <sup>a</sup>	.367 <sup>a</sup>	.282 <sup>a</sup>	.028 <sup>a</sup>	.044 <sup>b</sup>	
F	.205 <sup>a</sup>	.158 <sup>a</sup>	.915 <sup>a</sup>	.723 <sup>a</sup>	.057 <sup>a</sup>	.980 <sup>b</sup>	.181	.688	

<sup>a</sup>t-test, <sup>b</sup>Mann-Whitney test

In absolute numbers, the mean number of foramina was almost equal between both sexes (mean number of foramina in males = 2.17; mean number of foramina in females = 2.26). Of 216 foramina, 131 were found in the mandibular symphysis region (60.6%), 46 on the right (21.3%) and 39 on the left side of the mandible (18.1%). Specifically, of the 131 lingual foramina found in the region of the mandibular symphysis, 69 (52.7%) were localized in Region 2, 12 (9.2%) were in Region 5 and 50 (38.1%) were in Region 8. Of the 46 lingual foramina found on the right side in the anterior region of the mandible, six (13.0%) were localized in Region 3, six (13.0%) were in Region 6 and 34 (74.0%) were in Region 9. Of the 39 lingual foramina found on the left side of the lingual surface in the anterior region of the mandible, six (15.4%) were localized in Region 1, six (15.4%) were in Region 4 and 27 (69.2%) were in Region 7. No differences were found between the localizations ( $P = .349$ ) as well as type of dentition ( $P = .580$ ) in male and females patients (Table 1). Considering the measurements of parameters A, B, C, D, E and F, no significant differences were found between males and females ( $P > .05$ ) (Table 2).

Analyzes were conducted using mean values for parameters A, D and F and using median values for parameters B, C, and E (Figure 2). On the other hand, significant differences were found between males and females for the measurements D in region 9 ( $P = .009$ ) and E in regions 8 ( $P = .028$ ) and 9 ( $P = .044$ ) (Table 3).

## DISCUSSION

A deeper understanding about the lingual foramina and their anatomic variations is crucial in areas such as implant dentistry, oral maxillofacial and periodontal surgery, particularly at the time of performing local anesthesia, osteotomies and/or dissection of nerves. This is particularly the case at the time of performing perforations for the fixation of implants, due to the fact that it has been confirmed that blood vessels and fillets of nerves cross the foraminal canals<sup>3,7,9,10</sup>. Therefore, the present study provided important information to aid dental professionals in surgery planning and execution.

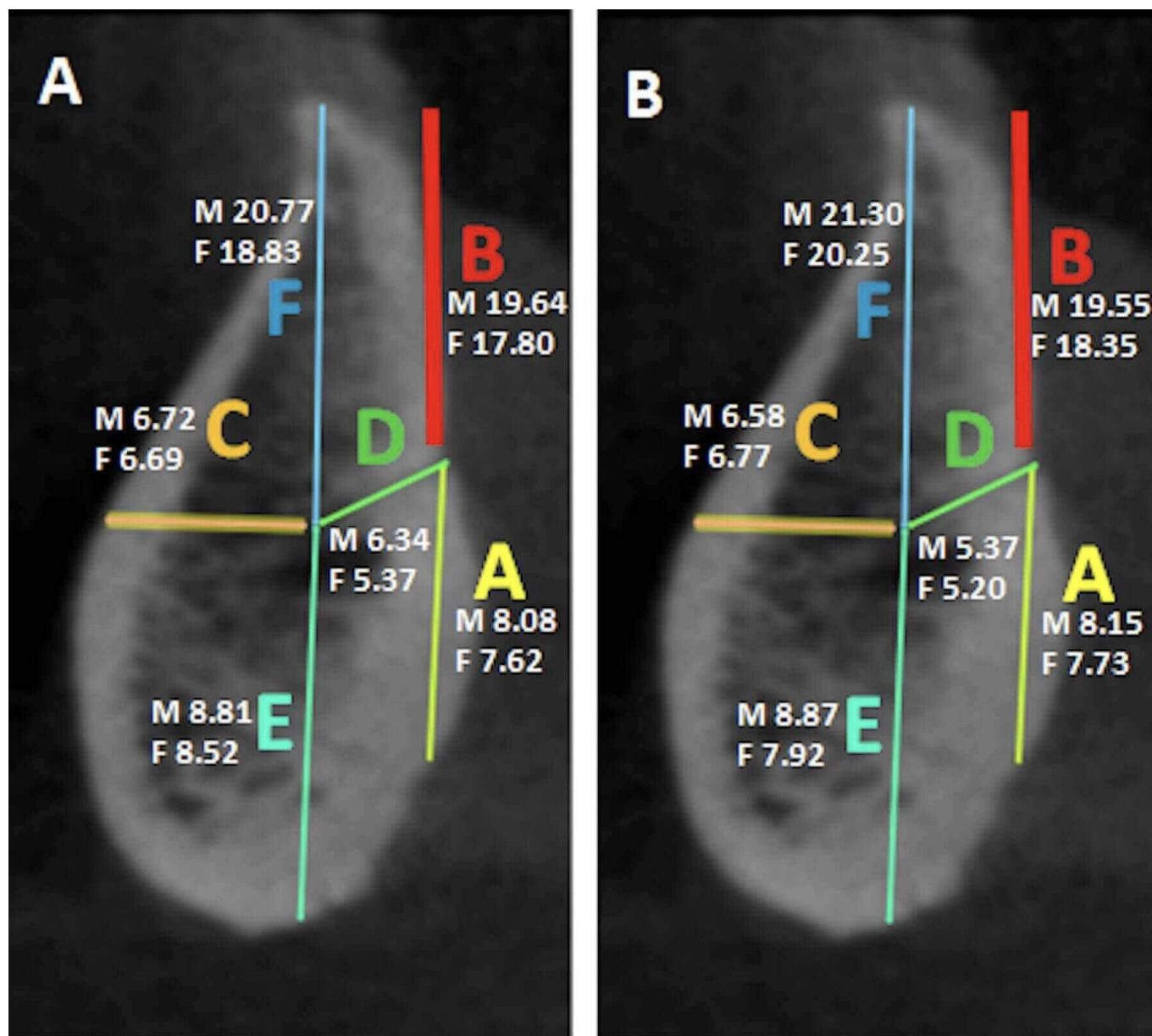


Figure 2. Cone-beam computed tomography (CBCT) in sagittal section of the mandible, representing the parameters analyzed for the lingual foramina. A- Mean values in males (M) and females (F). B- Median values in males (M) and females (F)

The majority of the lingual foramina in the anterior region of the lingual surface of the mandibular body were observed in the symphysis region. These data are in accordance with previous findings in Turkish<sup>2</sup>, Indian<sup>2</sup>, and Brazilian<sup>3</sup> populations. This finding revealed the importance of considering the presence of these foramina in the mandibular symphysis, because vascular and nerve structure pass through them and represent a danger zone during surgical procedures. Considering that the regions of the lingual surface of the anterior region of the mandible were delimited in quadrants to determinate the localization of the foramina, the present study revealed that the region in which the presence of lingual foramen was most common was Region 2 (31.9%) of the internal surface of the mandible. That is, foramina were present above the superior genial spine, corroborating previous findings<sup>3</sup>. The data obtained in this study also revealed that another region, frequently associated with the presence of these structures, was situated below the inferior genial spine (Region 8), which is in agreement with a study<sup>10</sup> conducted in mandibles of Italian cadavers. Another most frequent site was Region number 9 (15.7%), however no correspondence was observed with the results shown in other studies. The number of foramina observed in each patient ranged from one to five. Descriptively, the majority of patients had two foramina, on average. This aspect was an interesting point of this study, because no other studies that evaluated the patients in this manner were found in the literature.

In some researches, lingual foramina were described in the anterior region of the lingual surface of the mandibular body in all the studied patients<sup>11,12</sup>, although no mention was done on the quantity of these bone accidents in each individual. The literature has revealed the need for comparing the measurements of bone accidents between the sexes to obtain improved anatomic knowledge, in addition to adequate guidance to aid in surgical planning and execution. Therefore, the present study compared the mean and median values obtained in male and female patients and no statistical differences were observed in general measurements. However, significant differences between males and females were found for the measurements D in region 9 and E in regions 8 and 9. Overall, this finding suggested that irrespective of the procedure being performed on the lingual surface in the anterior region of the mandible, in Brazilians, it is far more relevant to consider the presence of foramina than the difference between sexes. Worth emphasizing is that in the literature, no studies were found that analyzed the presence and distribution of lingual foramina according to these parameters. Therefore, this was a pioneering study in this method of evaluation.

## CONCLUSION

This study revealed some important characteristics and anatomical aspects of the mandibular bone structure in relation to the lingual



foramina in a Brazilian sample. The comparison of the measurements performed on male and female patients showed differences in some parameters. In addition, the detection of regions with a greater number of occurrences of the lingual foramen, such as the symphysis of the mandible, draws attention to the need of careful planning and accurate execution of surgical procedures on the lingual surface of the anterior mandible.

**Conflict of interest:** The authors declare no conflict of interest.

**Acknowledgements:** The authors thank the “Coordenação de Aperfeiçoamento de Pessoal de Nível Superior” – CAPES (Coordination for the Improvement of Higher Education Personnel), Conselho Nacional de Desenvolvimento Científico e Tecnológico (CNPq) and the “Fundação de Amparo à Pesquisa do Estado de Minas Gerais” – FAPEMIG (Minas Gerais State Research Support Foundation) for funding and supporting the research.

## REFERENCES

1. Sekerci, A.E., Sisman, Y., Payveren, M.A. 2014. Evaluation of location and dimensions of mandibular lingual foramina using cone-beam computed tomography. *Surg Radiol Anat.*, 2014 Nov; 36(9):857–64.
2. Murlimanju, B.V., Prakash, K.G., Samiullah, D., Prabhu, L. V., Pai, M.M., Vadgaonkar, R., & Rai, R. (2012). Accessory neurovascular foramina on the lingual surface of mandible: incidence, topography, and clinical implications. *Indian J Dent Res.* 2012 May-Jun; 23(3): 433.
3. Deana, N.F., Navarro, P., Alves, N. (2018). Morphometric study of lingual foramina in macerated mandibles to assist in implant placement in the anterior mandibular region. *Folia Morphol (Warsz)*. 77(2): 310–22.
4. Morikage, N., Hamada, T., Usami, A., Takada, S. (2017). Topographical relationship between positions of lingual foramina and attachment of mylohyoid muscle in mental region. *Surg Radiol Anat.*, 2017 Jul; 39(7): 735–9.
5. Bernardi, S., Bianchi, S., Continenza, M.A., Macchiarelli, G. (2017). Frequency and anatomical features of the mandibular lingual foramina: systematic review and meta-analysis. *Surg Radiol Anat.* Dec; 39(12): 1349–57.
6. He, X., Jiang, J., Cai, W., Pan, Y., Yang, Y., Zhu, K., Zheng, Y. (2016). Assessment of the appearance, location and morphology of mandibular lingual foramina using cone beam computed tomography. *Int Dent J.*, Oct; 66(5): 272–9.
7. Neves, F.S., Torres, M.G., Oliveira, C., Campos, P.S., Crusoé-Rebello, I. (2010). Lingual accessory mental foramen: a report of an extremely rare anatomical variation. *J Oral Sci.*, 2010 Sep; 52(3): 501–3.
8. SanomiyaIkuta, C.R., Paes da Silva Ramos Fernandes, L.M., Poleti, M.L., Alvares Capelozza, A.L., Fischer Rubira-Bullen, I.R. 2016. Anatomical Study of the Posterior Mandible: Lateral Lingual Foramina in Cone Beam Computed Tomography. *Implant Dent.* 2016 Apr; 25(2): 247–51.
9. Kawai, T., Asaumi, R., Sato, I., Yoshida, S., Yosue, T. (2007). Classification of the lingual foramina and their bony canals in the median region of the mandible: cone beam computed tomography observations of dry Japanese mandibles. *Oral Radiology.* 2007 Dec; 23(2):42-8.
10. Rosano, G., Taschieri, S., Gaudy, J.F., Testori, T., Del Fabbro, M. 2009. Anatomic assessment of the anterior mandible and relative hemorrhage risk in implant dentistry: a cadaveric study. *Clin Oral Implants Res.* 2009 Aug; 20(8): 791–5.
11. Babiuc, I., Tărlungeanu, I., Păuna, M. (2011). Cone beam computed tomography observations of the lingual foramina and their bony canals in the median region of the mandible. *Rom J Morphol Embryol.*, 52(3): 827–9.
12. von Arx, T., Matter, D., Buser, D., Bornstein, M.M. (2011). Evaluation of location and dimensions of lingual foramina using limited cone-beam computed tomography. *J Oral Maxillofac Surg.*, 2011 Nov; 69(11): 2777–85.

\*\*\*\*\*